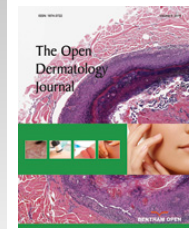




# The Open Dermatology Journal

Content list available at: [www.benthamopen.com/TODJ/](http://www.benthamopen.com/TODJ/)

DOI: 10.2174/1874372201610010027



## Atrophosclerodermic Manifestations of Lyme Borreliosis

Elisabeth Aberer\* and Nora Wutte

Department of Dermatology Medical University of Graz Auenbrugger Platz 8 A-8036 Graz, Austria

**Abstract:** This review summarizes the literature on scleratrophic skin lesions as a manifestation of a *Borrelia* infection. An association of morphea with Lyme borreliosis was mainly reported from Middle-European Countries, Japan and South America. *B. afzelii* has been identified predominantly from the chronic skin lesions of acrodermatitis chronica atrophicans (ACA) and has been cultivated from morphea lesions in isolated cases. Scleratrophic skin lesions like morphea, lichen sclerosus et atrophicus (LSA) and anetoderma have been observed in coexistence with ACA. Since all these diseases show clinical and histological similarities, they might have a common origin. The laboratory results that point to a borrelial origin of these diseases, however, are contradictory. Antibodies against *B. burgdorferi* were detected in up to 50% of patients. *Borrelia* DNA was shown in up to 33% of morphea and 50% of LSA patients. *Borrelia* were visualized on histological slides by polyclonal antibodies in up to 69% of morphea and 63% of LSA patients. In other reports no evidence of *Borrelia* – associated morphea or LSA has been reported. For anetoderma, single case reports showed positive *Borrelia* serology and/or PCR and a response to antibiotic treatment. The response of scleratrophic skin lesions to antibiotic treatment varies and can be seen in patients with or without a proven association to a *Borrelia* infection. This suggests that scleratrophic diseases might be of heterogeneous origin, but a *Borrelia* infection could be one cause of these dermatoses.

**Keywords:** *B. burgdorferi* sensu lato, Lyme borreliosis, Acrodermatitis chronica atrophicans, Morphea, Localized scleroderma, Lichen sclerosus et atrophicus, Meningo-radiculoneuritis, Anetoderma.

### INTRODUCTION

Lyme borreliosis (LB) is a world-wide infectious disease with classical clinical manifestations in the skin, namely erythema migrans (EM) and borrelia lymphocytoma in the early and acrodermatitis chronica atrophicans (ACA) in the late stage.

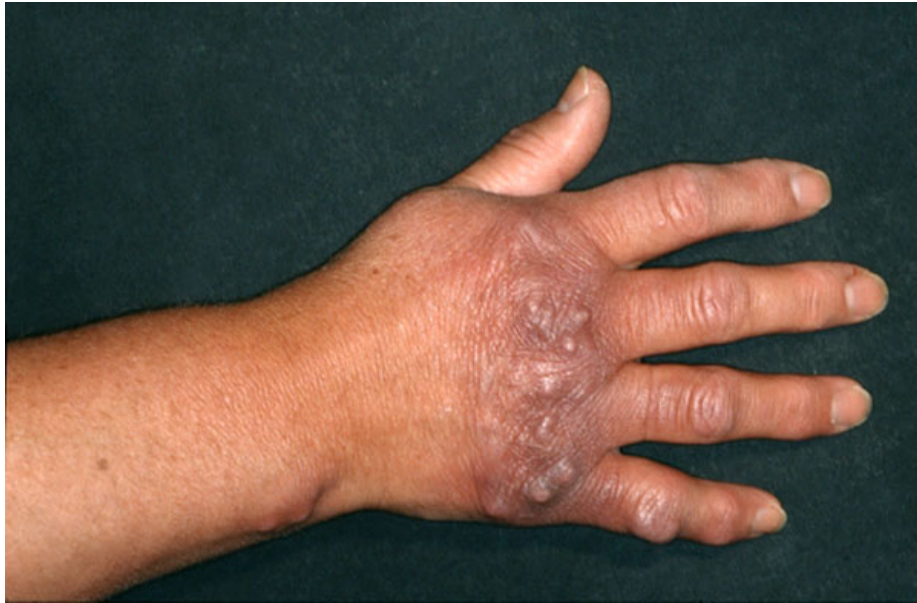In 1985 three research groups first suggested that morphea (localized scleroderma) could be another manifestation of a *Borrelia burgdorferi* infection [1 - 3]. The detailed development of research work in morphea and lichen sclerosus et atrophicus (LSA) and the association with LB was reviewed by Weide *et al.* in 2000 [4]. A complete summary of findings on the role of *B. burgdorferi* using serology, culture, PCR, immunohistochemistry, silver staining, lymphocyte stimulation test and treatment response has been published. The findings were also classified according to the respective geographic areas and countries. In 2000 and 2010, further reviews were published addressing the detection of *Borrelia* DNA by PCR-based methods in morphea and lichen sclerosus et atrophicus (LSA) [5, 6].

### FIBROTIC CHANGES IN ACA, COEXISTENCE WITH MORPHEA AND LICHEN SCLEROSUS ET ATROPHICUS

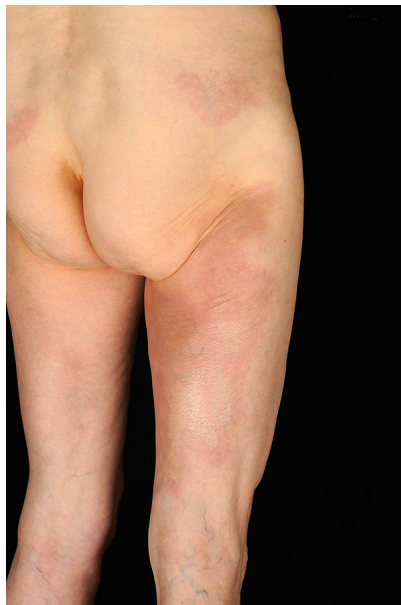Asbrink was one of the first to observe sclerotic changes in ACA in the context of a *Borrelia* infection [7]. Juxtaarticular nodules occur in 10-25% of ACA patients (Fig. 1). These can arise after the onset of ACA [8], or also as an isolated manifestation of LB (authors' observation). There have been a number of reports of localized or widespread fibrotic lesions in *B. burgdorferi* infection, as well as coexistence of ACA and morphea [8 - 14] (Fig. 2). Among 10

\* Address correspondence to this author at the Department of Dermatology Medical University of Graz, Auenbrugger Platz 8 A-8036 Graz, Austria; Tel: 0043-316-385-13926; Fax: 0043-316-385-12466; Email: [elisabeth.aberer@medunigraz.at](mailto:elisabeth.aberer@medunigraz.at)

seropositive morphea patients, Büchner *et al.* described 2 patients with a history of EM, 1 with coexisting ACA, and 2 with LSA [15]. In 1994 Trevisan *et al.* reviewed the association of *B. burgdorferi* and localized scleroderma [16].



**Fig. (1).** Fibrous nodules in acrodermatitis chronica atrophicans.



**Fig. (2).** Acrodermatitis chronica atrophicans with pseudoscleroderma and erythematous patches on the buttock presenting early morphea.

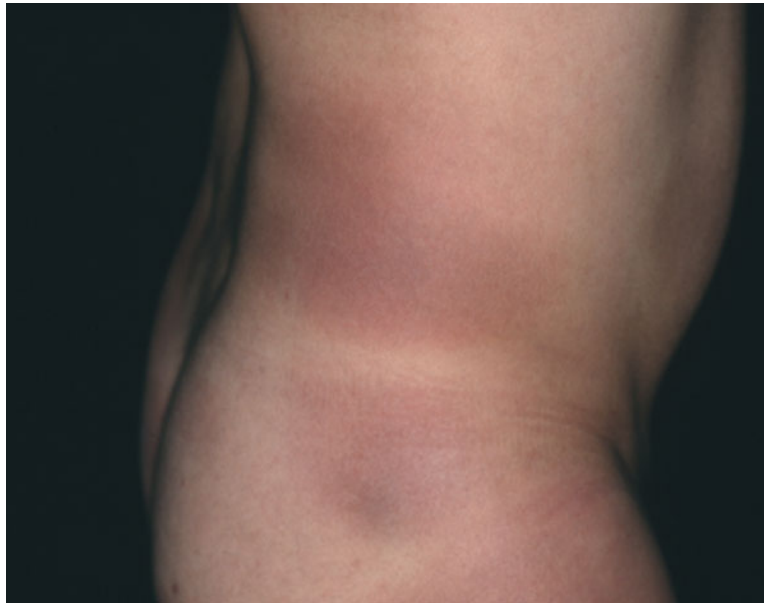ACA was described in association with genital and extragenital LSA, tubulo-interstitial nephritis and spirochetes in urine that were seen one year after a tick bite [17]. ACA, LSA and nephritis regressed after antibiotic therapy.

#### **MORPHOLOGICAL FINDINGS IN MORPHEA, LSA AND ACA**

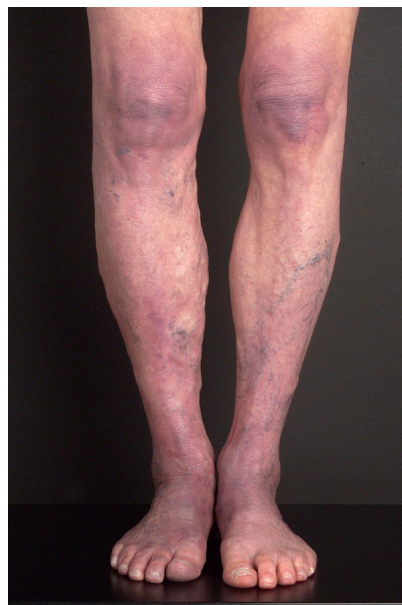Clinically, early morphea cannot be distinguished from EM, and persisting EM cannot be distinguished from early morphea in terms of clinical or histological features in some patients. Morphea can mimic ACA as well, with a livid discoloration (Fig. 3). Whereas ACA involves acral body sites with lower temperatures, is located on the extensor surfaces of extremities and not sharply demarcated (Fig. 4), morphea is sharply demarcated, appears as single or multiple plaques that can be linear, and/or deep (including fasciitis) with possible confluence of lesions, affects any age

and body site, and enlarges at the periphery of the lesions with the typical lilac ring.

Morphea is a disease of heterogeneous origin occurring after vaccination, trauma, or insect bites; it can also be congenital [18]. Histologically, the early phase is associated with edematous swelling of collagen fibers, perivascular and interstitial infiltration of lymphocytes, monocytes, histiocytes, eosinophils and plasma cells, followed by collagen overproduction or atrophy [19]. Serup divided the connective tissue changes in morphea into fibril degradation and myxedematous, cell infiltration and fibrotic stages [20]. Upon electron microscopy, collagen changes include loss of their transverse striation, disintegration of fibers, elastoid transformation and complete collagen destruction [21].



**Fig. (3).** Livid patches of morphea on the trunk. Culture of a skin biopsy was positive. *B. afzelii* was identified by PCR-RLFP analysis [111].



**Fig. (4).** Acrodermatitis with atrophic skin changes.

Histologically, ACA shows both a band-like subepidermal and a perineural cell infiltrate, atrophy of collagen with edematous or thinned collagen fibers, and fibrosis. There are no important differences between the lesional skin of ACA, fibrous nodules, ulnar bands or sclerodermatous changes [22]. Electron microscopy shows that elastic fibers are destroyed and collagen fibers are present with peripheral amorphous material in ACA [23], showing similarities to the

described changes in morphea [21].

Comparing the histological features and the inflammatory infiltrate in 19 ACA and 40 morphea biopsies, histological differentiation from ACA was not possible in 17% of morphea cases regardless of positive or negative *B. burgdorferi* serology [24]. Both diseases display basal cytolysis of keratinocytes. In ACA the inflammatory infiltrate shows a lichenoid, in morphea a perivascular pattern. Hypertrophic basophilic elastic tissue is seen in ACA, whereas in morphea the elastic tissue is preserved and polarizing. The histological pattern of morphea could not be associated with a particular clinical type of morphea or with positive *B. burgdorferi* serology with exception of atrophoderma Pasini-Pierini, where an association with a *Borrelia* infection could not be detected in that study [25]. Thus, a *Borrelia* etiology cannot be established from a morphological pattern in morphea.

LSA also shows an atrophic epidermis with basal layer vacuolization [26]. The superficial dermis is edematous and hyalinized with disappearance of elastic fibers, although there is an increase in elastic fibers in the mid and lower dermis. Collagen degeneration and regeneration were observed ultrastructurally in the superficial dermis with higher amounts of ground substance [27]. Collagen fibers were also observed to be phagocytized by fibroblasts [28]. Coexistence of LSA with morphea was observed in 27 of 472 (5.7%) patients [29].

In summary, ACA, morphea and LSA share histopathological similarities like vacuolization of basal keratinocytes and loss of collagen; ACA and morphea the fibrosing tissue reaction; and ACA and LSA loss and proliferation of elastic fibers.

## METHODS

A PubMed search was performed in December 2014 with the following key words: 1) “morphea, borreliosis”: 97 papers were published in the last 30 years with original publications, case series, case reports and reviews showing an association with a *B. burgdorferi* infection or no evidence. The majority of these publications are analyzed in this review. 2) “anetoderma, borreliosis” produced 6 papers, 4 of them case reports and 2 of them reviews pointing out that sclerotic and atrophic lesions of morphea can be observed in the spectrum of LB. 3) “atrophy, borreliosis, skin”: 26 papers were published, 14 of them about ACA, 6 about scleratrophic findings, and 3 about Parry-Romberg syndrome; there were also 3 reviews and other miscellaneous papers.

Table 1 lists research papers on morphea and LSA in relation to a *Borrelia* infection that have been published since 2000; Table 2 lists publications about anetoderma; and Table 3 lists clinical cases of sclerotic skin lesions that were treated with antibiotics.

**Table 1. Reports on the association of *B. burgdorferi* with morphea and lichen sclerosus et atrophicus since 2000.**

Author, year, country	No. of patients/controls	Serology % pos. (pos./ no. of patients)	PCR % pos (pos./ no. of patients)/primer	Immuno-histochemistry % pos. (pos./ no. of patients)/used antibodies
Özkan S [5] 2000 Turkey	10 morphea 12 LSA 10 controls	n.d.	33% (3/10) 50% (6/12) nested PCR, flagellin primer	n.d.
Svecova D [38] 2000 Slovakia	32 morphea 7 LSA 131 controls 55 LB patients	34.4% (11/32) 71.4% (5/7) 33.6% (44/131) 100% (55/55)	n.d.	n.d.
Wojas-Pelc A [39] 2002 Poland	50 morphea	28.5% ANA 18%	n.d.	n.d.
Espinoza-Leon F [55] 2006 Venezuela	21 morphea 21 controls	14% (3/21) 4.7% (1/21) positive by ELISA not confirmed by IB	n.d.	n.d.
Sommer A [54] 2006 Germany (Bochum)	12 hemiatrophia faciei	3 positive ELISA not confirmed by IB	n.d.	n.d.
Eisendle K [59] 2007 Austria	122 morphea 10 controls with pos PCR 58 controls with neg PCR	n.d.	1/30 nested PCR <i>B. burgdorferi</i> 23S rRNA	69% (84/122) 100% (10/10) 0% (0/0) polyclonal antibodies
Eisendle K [110] 2008 Austria	60 LSA 68 controls (classic LB)	n.d.	n.d.	63% (38/60) 90% (61/68) polyclonal antibodies, FFM

(Table 3) contd.....

Author, year, country	No. of patients/controls	Serology % pos. (pos./ no. of patients)	PCR % pos (pos./ no. of patients)/primer	Immuno-histochemistry % pos. (pos./ no. of patients)/used antibodies
Prinz JC [40] 2009 Germany (Bavaria) Hungary	90 morphea	22% (20/90) ANA 47% (42/90)	n.d.	n.d.
Zollinger T [6] 2010 Switzerland	49 morphea 15 LSA 48 controls (granuloma anulare)	n.d.	2% (1/49) 7% (1/15) 2% (1/48) /nested PCR; sequence analysis: <i>B. burgdorferi</i> sensu stricto	n.d.
Espinoza-Leon F [69] 2010 Venezuela	21 morphea	n.d.	0 % (0/21)	n.d.
Santos M [60] 2011 Amazonic region	15 morphea, atrophoderma Pasini-Pierini, LSA	n.d.	n.d.	26.6% (4/15) / FFM

FFM: focus floating microscopy, IB: immunoblot LSA: lichen sclerosus et atrophicus; n.d: no data

## EVIDENCE OF *B. BURGDORFERI* INFECTION IN MORPHEA (TABLE 1)

### Serology

In the review of Weide *et al.* covering 1985 to 2000, a total of 138 among 609 morphea cases with positive anti-*B. burgdorferi* antibodies were reported from Austria, Germany, Italy, Poland, Slovakia, and Switzerland [4, 25, 30 - 38]. Table 1 lists the publications since 2000 that show a possible association of morphea with *B. burgdorferi* infection. Anti-*B. burgdorferi* antibodies were reported in 22 - 34.4% of morphea patients [38 - 40]. Wojas-Pelc *et al.* showed positive *B. burgdorferi* serology in 28.5% and positive ANA in 18% [39]. Prinz *et al.* observed that seropositive patients with early-onset morphea had high ANA titres [40].

Negative or negligible serologic findings were reported from Denmark, England, Finland, France, Japan, Netherlands, Spain, Venezuela, and USA [41 - 55].

### Morphological Detection of *B. burgdorferi* by Immunohistochemistry or Silver Staining

In 1987 Aberer *et al.* detected *Borrelia* in 7/21 biopsies of morphea patients by immunohistochemistry. Diluted serum from an ACA patient was used and *Borrelia* were visualized by high-power resolution videomicroscopy [56]. In a further study *Borrelia* were detected in 25% of morphea, EM and ACA biopsies [57]. *Borrelia* could also be visualized by silver staining in 10/25 morphea patients in Puerto Rico [58], and by a polyclonal antibody in 84/122 morphea patients using focus floating microscopy (FFM) [59]. Only 1 of these 30 patients was positive by PCR. With FFM, *Borrelia* were detected in morphea in 3/15 patients in Brazil, LSA and atrophoderma [60] and in a case of a boy with early-onset morphea with tight skin, whereby PCR was negative [61]. Immunohistochemistry was negative in 14 morphea biopsies [47] as well as Elias-Bosma staining in 13 morphea patients [62].

### PCR

In 1993 Schempp *et al.* showed *B. burgdorferi*-specific DNA with flagellin primers of the 16s-RNA gene in lesional skin of patients with morphea [48]. In a follow-up study, the results of the positive PCR were compared, since patients' biopsies were derived from 3 different countries. Whereas some of the biopsies of German and Japanese patients were positive, biopsies from the USA were negative [63]. PCR was positive in seropositive and seronegative Italian morphea patients [37]. Nested PCR was performed for Turkish morphea patients and 3/10 of them were positive [5]. *Borrelia* DNA was detected in different sclerodermiform skin lesions [64, 65]. Amplification of DNA sequences of *B. burgdorferi* by nested PCR, and proven by sequencing was only positive in 1/49 morphea patients in Switzerland [6]. No *Borrelia*-specific DNA has been detected in morphea lesions in several other studies from Finland, Netherlands, Spain, USA [49 - 51, 53, 66 - 69] and also in one study from Germany [33].

### Culture

*B. burgdorferi* from skin biopsies of morphea was only cultured for a minority of patients, with low outcome [56, 70] (Fig. 3). *B. afzelii* was cultured from a seronegative patient with widespread morphea identified by SDS

polyacrylamide-electrophoresis of outer surface proteins [71]. Further studies culturing *B. burgdorferi* from morphea were negative [47, 49, 53].

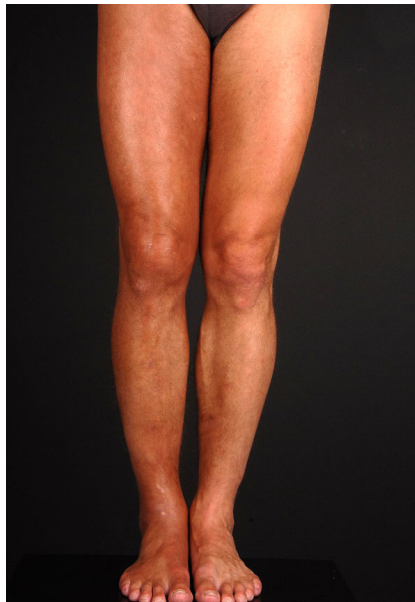### Lymphocyte Transformation Test (LTT)

In 1993 Büchner *et al.* found significantly elevated lymphoproliferative responses in 10 seropositive morphea patients [15]. In a further study lymphoproliferative responses were measured in 45 patients with morphea compared to 21 healthy seronegative controls and patients with EM, lymphadenosis benigna cutis and ACA. Stimulation indices in morphea patients did not differ significantly from the normal population [34].

LTT was positive in a single seronegative morphea case with positive PCR by flagellin primers and immunohistochemical detection of *B. burgdorferi* in the skin [72]. Breier *et al.* reported elevated mean stimulation indices in 11/39 (28%) of seropositive and seronegative morphea patients; these were nearly as high as in patients with EM compared to ACA, seropositive LB patients and healthy controls [36].

### Eosinophilic Fasciitis/Shulman Syndrome/Parry-Romberg Syndrome

Positive *Borrelia* serology and an association with LB were often reported in eosinophilic fasciitis/Shulman syndrome (Fig. 5) [73 - 78], with detection of a positive flagellin gene sequence by PCR in one patient [79]. In 4 cases of borrelial fasciitis, spirochetal organisms were identified by Dieterle and Steiner silver stains; one patient was positive with a rabbit polyclonal antibody; 2/4 patients were seropositive [80].



**Fig. (5).** Eosinophilic fasciitis arising in the context of Lyme arthritis of the knee on the same extremity.

No clear association with *Borrelia* infection was shown in Parry-Romberg syndrome [81 - 83]. In a retrospective study, 2 of the 12 patients with hemiatrophy were seropositive by ELISA that was not confirmed by IB [54]. In one Italian patient with linear scleroderma “en coup de sabre” with facial atrophy, antibodies against *B. burgdorferi* were positive [84].

### EVIDENCE OF *B. BURGDORFERI* INFECTION IN LICHEN SCLEROSUS ET ATROPHICUS (TABLE 1)

There are only limited studies on the determination of anti-*B. burgdorferi* antibodies in LSA. Svecova *et al.* from Slovakia found 5/7 seropositive LSA patients [38], and Aberer *et al.* 2/13 seropositive LSA patients [56].

### Immunohistochemistry/Silver Staining

In 6/13 patients with genital and extragenital LSA, *Borrelia* could be detected by immunohistology after staining with a 1:20 diluted serum from a patient with high antibody titers against *B. burgdorferi* visualized by videomicroscopy [56]. Using FFM, Eisendle *et al.* detected *Borrelia* species in 38 of 60 cases (63%) of lichen sclerosus and in 61 of 68



(90%) positive controls of classic borreliosis, but *Borrelia* species were absent in all negative controls. *Borrelia* species were detected significantly more often in early inflammatory-rich (31 of 39 80%) than in late inflammatory-poor (7 of 21 33.3%) cases ( $P = .001$ ). Polymerase chain reaction findings were positive in 25 of 68 positive controls (37%) and negative in all 11 cases of lichen sclerosus and all 15 negative controls [85].

### PCR in Skin Biopsies

Özkan *et al.* demonstrated the presence of *B. burgdorferi* DNA in 6/12 patients with LSA by a nested PCR using European flagellin gene primer sets [5]. In contrast, negative molecular biological findings were reported in LSA biopsies by PCR using OspA or flagellin or clone 2H1 primers [53, 66, 67].

Zollinger *et al.* performed a PCR-based study and reviewed the literature. The authors could only detect *Borrelia* specific DNA in 1/15 (6.6%) LSA patients (1/49 morphea, 1/48 granuloma annulare) and assumed that *B. burgdorferi* does not play a significant role in these diseases [6].

### Urine PCR

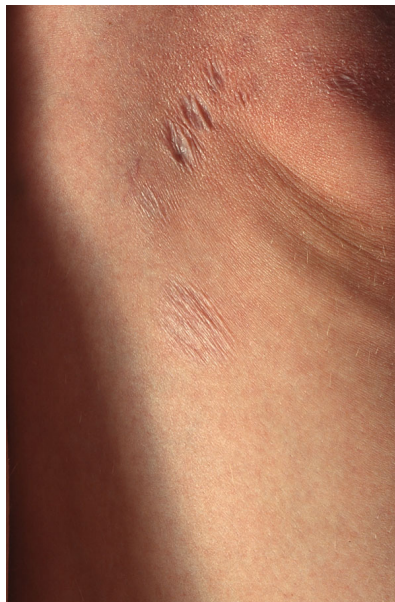Amplification of *Borrelia* DNA in the urine was positive by flagellin primer in 13/19 patients with LSA (none in 23 healthy controls and 49 patients with various dermatologic diseases except in granuloma annulare in 8/13 urines [86].

### CULTURE

Culture for *B. burgdorferi* was negative in 1 investigated LSA patient [53].

### ATROPHIC LESIONS IN LYME BORRELIOSIS (TABLE 2)

Anetoderma is defined by a decreased amount of dermal elastic tissue and a variable amount of inflammatory infiltrate [87]. A patient with multiple oval skin colored macules with a wrinkled surface is reported. PCR analysis for the flagellin gene and genotyping were positive for *B. afzelii*. Strunk *et al.* reported another patient with positive IgM antibodies to *B. burgdorferi* and arrested progression of anetoderma after doxycycline [88].



**Fig. (6).** Anetoderma at the border of an ACA lesion after antibiotic therapy.

Anetoderma was also observed with and without association to ACA proven by ELISA, IB and amplification of *B. afzelii*-specific DNA from skin [89]. Similarly, Bauer *et al.* reported anetoderma with positive PCR using the 23 S ribosomal RNA gene and increased IgG antibodies against *B. burgdorferi* by IB [90].

Congenital anetoderma was reported by Aberer and Weißenbacher in a newborn showing atrophic livid patches on the chest with progression in the first weeks of life. Antibodies against *B. burgdorferi* were negative in the baby and the mother, so LB was not proven. Treatment with ceftriaxone for 14 days stopped the progression and there was no

wrinkling. Anetoderma so was not proven; the lesions rather correspond to atrophic morphea since deep structures like fat and muscle were also involved [91].

The pathogenic relationship between ACA and anetoderma is striking since the histological changes are very similar and both diseases have been described in association [89]. Atrophic wrinkled patches can remain after treatment of ACA (Fig. 6). Atrophic elastic tissue is observed among the inflammatory infiltrate in ACA, and elastic fibers, having been engulfed in HLA-DR positive cells, are HLA-DR positive [24].

**Table 2. Anetoderma in Lyme borreliosis.**

Reference	Diagnosis	Detection method	Outcome
Aberer E [91] 1997 Austria	Congenital anetoderma induced by intrauterine infection?	<i>B. burgdorferi</i> - antibodies neg. in mother and child	Complete resolution with ceftriaxone for 14 days with persisting atrophy of skin and fatty tissue, no recurrence after 8 years
Bauer J [90] 2003 Germany	Anetoderma: another facet of Lyme disease	Positive PCR with 23S ribosomal RNA gene, positive <i>B. burgdorferi</i> IgG-antibodies	Doxycycline 100mg bid 30 days; no new lesions
Hofer T [89] 2003 Switzerland	Anetoderma and LB: is there a pathogenetic relationship? (2 patients)	<i>B. afzelii</i> -specific DNA, positive <i>B. burgdorferi</i> antibodies	Improvement after doxycycline 200mg 28-30 days in both patients
Trevisan G [112] 2008 Italy	Anetoderma associated with Lyme disease	Nested PCR from skin biopsy and tissue culture positive; genotyping revealed <i>B. afzelii</i>	Penicillin G 20 Mill U/d in 4 doses 14 days; Amoxicillin bid 21 days; No further anetoderma lesions over a period of 6 months
Strunk T [88] 2011 Germany	Anetoderma with positive <i>Borrelia</i> serology	Positive <i>B. burgdorferi</i> - IgM antibodies	Doxycycline 100mg bid; progression arrested

### CLINICAL REPORTS OF THE ASSOCIATION OF SCLEROTIC LESIONS WITH *B. BURGDORFERI* INFECTION AND THE EFFECT OF ANTIBIOTIC TREATMENT (TABLE 3)

After penicillin treatment, a seropositive patient with morphea profunda on the flexor aspects of the thigh was remarkably improved [9]. *Borrelia* infection was proven by detection of specific *B. burgdorferi* DNA and IgG antibodies in a patient with sclerodermiform skin lesions of the extremities and polyneuropathy with improvement of dermatologic and neurologic symptoms after ceftriaxone [65].

Repeated oral treatment with penicillin V and/or doxycycline for 20-30 days was effective in 6 among 30 patients with different types of morphea [25]. The lilac ring disappeared and the sclerotic plaques gradually smoothed in 8 patients treated with penicillin G 10 Mill IU intravenously bid for 14 days. Three patients unresponsive to systemic penicillin therapy responded to ceftriaxone. Two patients treated with ceftriaxone 2g for 15 days and 1 patient treated with intravenous penicillin recovered completely. All 6 seronegative patients with atrophodermia Pasini-Pierini and 1 seropositive patient with livid atrophic patches showed progression in spite of antibiotic therapy.

Wackernagel *et al.* reported a patient with positive ANA and CENP-B antibodies and abrupt onset of diffuse erythemas and doughy swellings involving the face and the upper trunk, followed by thickening and induration of the skin mimicking diffuse systemic scleroderma. *B. burgdorferi* infection was proven by repeatedly positive urine PCR and positive *B. burgdorferi* ELISA confirmed by IB. The patient responded rapidly to intravenous treatment with ceftriaxone 2g for 20 days [92].

Gubertini *et al.* observed an association of LSA, scleroderma en coup de sabre and Lyme borreliosis shown by positive PCR in the skin biopsy, blood and urine. Improvement was achieved with two courses of ceftriaxone 2g for 21 days in combination with UVA-1/vitamin E therapy [93]. Fifteen lichen sclerosus patients from the United States without evidence of a *Borrelia* infection were treated for 3-21 months with either intramuscular benzathin penicillin, cephalosporins, or oral antibiotics in an observational study [94]. All patients showed a significant response within a few weeks. Treatment of lichen sclerosus with either intramuscular ceftriaxone every 3 weeks or intramuscular penicillin every 2-3 weeks is recommended.

Prinz *et al.* observed a correlation of *Borrelia*-associated morphea diagnosed by serology with positive ANA [40]. Twenty of 90 patients were seropositive although some patients had only IgM antibodies, which can be interpreted as non-specific. Antibiotic treatment with penicillin G or ceftriaxone for 21 days improved sclerosis and arrested progression. As all patients had concomitant UV therapy, the effect of antibiotic treatment cannot be assessed objectively.



Table 3. Treatment response in morphea.

Reference	Clinical cases	Detection method	Outcome
Büchner SA [9] 1990 Switzerland	Morphea profunda	Positive antibodies	Penicillin; remarkable improvement
Wackernagel A [92] 2005 Austria	Acute exacerbation of SSc in <i>Bb</i> infection	Positive PCR in urine; positive ELISA and immunoblot; genotyping <i>B. afzelii</i>	Complete resolution after antibiotic treatment with ceftriaxone 2g for 21 days
Kaya G [113] 2001 Switzerland	Chronic borreliosis presenting with morphea- and LSA-like cutaneous lesions	Positive PCR (290 bp-specific primer); positive IgM and IgG antibodies by immunoblot	Ceftriaxone 2g for 21 days; improvement after 7 days
Prinz JC [40] 2009 Germany	Multiple plaques and linear morphea	Positive IgM antibodies, Positive ANA	Ceftriaxone 2g for 21 days + UVA 1; no further progression, no relapse, reduced sclerosis
Prinz JC [40] 2009 Germany	Generalized morphea	Positive IgG antibodies, positive ANA, U1RNP-, Sm-antibodies	Penicillin G 10 mega units bid for 21 days + PUVA bath; reduction of sclerosis, relapse after 16 months
Prinz JC [40] 2009 Germany	Morphea with multiple plaques	Positive IgM antibodies, Positive ANA	Oral amoxicillin 500mg tid for 14 days + UVA 1; relapses
Gubertini N [93] 2011 Italy	LSA, scleroderma en coup de sabre	Positive PCR in blood, tissue, urine	2 cycles ceftriaxone 2g 21 days + UVA 1 and Vit. E; improvement
Migliano B [95] 2012 Italy	Localized scleroderma <i>unius lateri</i> and <i>B. burgdorferi</i> infection	Positive IgM antibodies, negative IgG antibodies Negative PCR	2 courses of benzathin penicillin 12 Mill IU/ day for 20 days; clear improvement after 4 months, softening of deep tissues

The response to antibiotic treatment in morphea and LSA is not dependent on a confirmed *Borrelia* infection. *Borrelia* DNA from peripheral blood and skin tissue was negative and only *B. burgdorferi* IgM antibodies were positive in a patient with left-sided painful scleratrophic plaques, progressive weakness and limb hypotrophy. After two courses of benzathin penicillin, there was clear improvement of skin lesions and softening of deep sclerotic plaques [95].

## DISCUSSION

Buechner *et al.* suggest that ACA is a chronic T-cell mediated disease leading to severe tissue damage with atrophy of the epidermis and connective tissue [96]. Fibrosis is a typical reaction pattern seen in LB, not only in the skin but also in other tissues like the heart [22, 97]. Heart ventricles of adult Macaca mulatta monkeys show large deposits of collagen and the presence of *Borrelia* after inoculation with the *B. burgdorferi* sensu stricto N40 strain [97].

*B. burgdorferi* has high affinity to collagen and could be detected among collagen fibers in ACA by electron microscopy [23]. *Borrelia* and their degenerative products were frequently located along or between collagen bundles in morphea, partially or completely hidden if not visualized in the correct section plane as shown by FFM [59] or forming colonies in the collagen in erythema migrans, as observed by videomicroscopy [57].

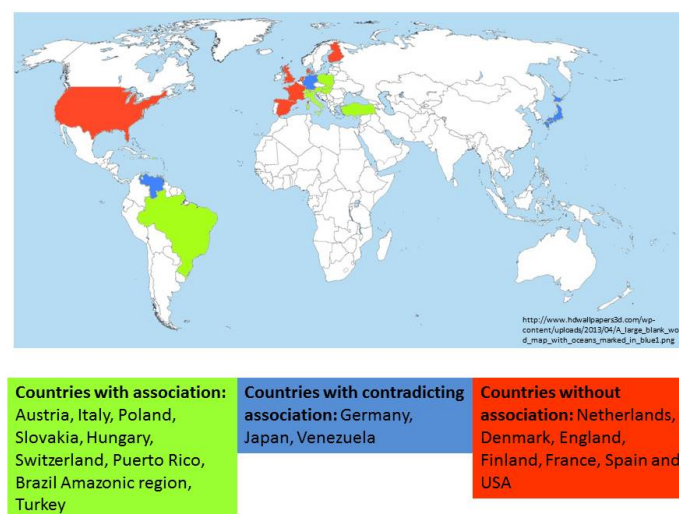
This affinity of *Borrelia* to collagen was also shown in *in vitro* experiments with invasion and colonization of native type I collagen lattices [98, 99]. Binding of *B. burgdorferi* to adhesins such as the glucosamine-binding protein [100], fibronectin-binding protein [101, 102] and the proteoglycan decorin has been described [103]. Furthermore, *B. burgdorferi* possesses collagenolytic activity and plasmin-coated *Borreliae* degrade the extracellular matrix [104, 105]. It was suggested by Ackerman that fibrosis results mainly as a consequence of collagen destruction. Fibroblasts attempt to repair the defect but they never completely restore the original state [106]. Similarly, an increase in elastic fibers in LSA may reflect a process to repair the degraded upper dermal elastic fibers [26]. Elastic fibers are also markedly reduced in the upper and very prominent in the deeper dermis in ACA [24]. Damage of elastic and collagen fibers by *B. burgdorferi* has been described [107].

Laboratory methods to detect LB have to be interpreted cautiously as some test results could be misinterpreted. ELISA and IB employ different antigens and techniques that vary in their sensitivity and specificity [16], and two-tiered testing is not routine. PCR is performed with different primers to detect DNA or RNA and various sequencing methods, so that the results of these tests are hardly comparable; interpretation methods also differ. In some studies, patients were seropositive by anti - *B. burgdorferi* IgM antibodies only; these are not specific for a *Borrelia* infection when IgG seroconversion does not follow [40, 95, 108], or when the ELISA cannot be confirmed by IB [55]. The association

between morphea and a *Borrelia* infection was reported from countries that tend to have a higher frequency of *B. burgdorferi* seroprevalence in the general population [16]. The results of laboratory findings and their interpretation are contradictory. When there was a small number of seropositive morphea patients, the serologic data were interpreted as a possible cross reaction, as in a paper by Hoesly *et al.*, who reported 6/32 positive patients from the USA [109]. No *Borrelia*-associated morphea cases were reported in the United States. On the other hand, Granter *et al.* in Boston detected *Borrelia* in tissue sections by silver staining or by a polyclonal antibody in 4 patients with diffuse fasciitis [80].

It takes experience to identify *B. burgdorferi* on histological slides from among the different *Borrelia* forms, since the morphology of *Borrelia* in tissues is very heterogeneous [57]. *Borrelia* can only be visualized with special techniques such as videomicroscopy or focus floating microscopy, and time resources also limit this special diagnostic technique. The number of *Borreliae* can be very low, so that a negative finding does not rule out a *Borrelia* infection, and the antibodies used have different sensitivities. *Borrelia* can also be identified in seronegative morphea and LSA cases. Moreover, *B. burgdorferi* was detected immunohistochemically, not only in skin biopsies of morphea and LSA but also in several other diseases like cutaneous B-cell lymphoma, lymphocytic infiltration, granuloma anulare, interstitial granulomatous dermatitis, as well as in isolated cases of cutaneous sarcoidosis, necrobiosis lipoidica and necrobiotic xanthogranuloma [110]. The specificity of these findings remains to be determined. *Borrelia* can survive in different tissues and visualizing this bacterium does not always mean that it is the pathogen causing the disease.

There are significant geographic differences in the reported scleratrophic *Borrelia* infections, with a higher prevalence in areas of middle Europe (Fig. 7) [6]. The results of most PCR-based studies do not argue for a significant association of *B. burgdorferi* with morphea and LSA, and PCR was only applied in limited studies. The contradictory findings might have discouraged researchers from any further search for an infectious origin of scleratrophic skin diseases. Treatment success with antibiotics has often been reported, but controlled studies have not so far been undertaken to prove their efficacy. Pencillin G has been successfully used for therapy of dermal fibrosis. The effect of penicillin has also been attributed to a non-antibiotic action involving collagen metabolism. Yet, the mechanism of the antifibrotic action of penicillin G is still unknown [114].



**Fig. (7).** World-wide reported *B. burgdorferi* - associated scleratrophic changes.

## CONCLUSION

The sclerotic/atrophic skin changes observed in LB vary, so several differential diagnoses might be relevant and should be distinguished from the putative LB-associated diseases (Table 4).

The possible relationship between scleroatrophic skin lesions with Lyme borreliosis is supported by 1) the similar clinical appearance of morphea with EM or ACA, 2) coexistence of morphea with ACA and/or LSA in the same patient, 3) the presence of a higher percentage of antibodies than in healthy controls, 4) positive PCR, 5) identification of *Borrelia* on histological sections, 6) culture of *B. burgdorferi* from skin lesions, and 7) the response to treatment of some patients. Treatment response was also reported from morphea cases without antibodies or without another proven

borreliar origin. Since morphea is a heterogenous disease, another microorganism might be causing it. It is also possible that a *Borrelia* infection cannot be proven because the laboratory techniques are not sensitive enough. Anetoderma can also be associated with ACA. In this rare disease, single case reports have shown anti - *B. burgdorferi* antibodies, positive *B. burgdorferi* DNA and response to antibiotic treatment.

**Table 4. Differential diagnoses of scleratrophic skin diseases.**

Morphea - pseudoscleroderma	Atrophic skin diseases
Granuloma anulare	Granulomatous slack skin
Systemic nephrogenic fibrosis	Steroid atrophy
Radiation fibrosis	Neurogenic atrophy
Chronic graft-versus host disease	Progeria
Lipodermatosclerosis	Striae cutis distensae
Skleromyxoedema	Atrophic scarring
Skleredema diabeticorum	Atrophy in skin aging
Skleredema adutorum Buschke	Atrophodermia vermiculata
Eosinophilia-myalgia syndrome	
Toxic oil syndrome	
Porphyria cutanea tarda	
Progeria syndromes	

There is a strong relationship between specific geographic areas with reported *Borrelia*-associated morphea cases and with the predominant genotype. *B. afzelii* was the predominant species that was isolated from ACA and *B. afzelii* DNA has been detected predominantly in skin lesions. Another cause for the different results in hitherto published studies is that sclerotic lesions can be misinterpreted since the pseudoscleroderma of ACA can easily be mistaken for morphea.

The pathologic changes in scleratrophic skin lesions point to connective tissues damage, which can be caused by *B. burgdorferi*. A high affinity of *Borrelia* to collagen and degradation of fibers is the central process that has not yet received attention. It can be assumed that the scleratrophic skin lesions can be caused by *Borrelia* infection in certain countries where *B. afzelii* is endemic. The response to antibiotic treatment in cases where there was no proven association to a *borrelia* infection suggests that other microorganisms might be involved in scleratrophic dermatoses and suggests that these diseases must be of heterogeneous origin.

To prove the Koch's postulates, transmission experiments that have been performed in EM, ACA and lymphadenitis cutis are missing for scleratrophic skin lesions. In future controlled multicenter studies with standardized laboratory techniques including placebo-controlled treatment studies should be performed in a well-defined morphea population to determine the role of *B. burgdorferi* in scleratrophic skin diseases.

## CONFLICT OF INTEREST

The authors confirm that this article content has no conflict of interest.

## ACKNOWLEDGEMENTS

Declared none.

## REFERENCES

- [1] Aberer E, Neumann R, Stanek G. Is localised scleroderma a *Borrelia* infection? *Lancet* 1985; 2(8449): 278. [http://dx.doi.org/10.1016/S0140-6736(85)90329-0] [PMID: 2862452]
- [2] Neubert U, Krampitz HE, Engl H. Microbiological findings in erythema (chronicum) migrans and related disorders. *Zentralbl Bakteriologie Mikrobiol Hyg A* 1986; 263(1-2): 237-52. [http://dx.doi.org/10.1016/S0176-6724(86)80127-4] [PMID: 3577483]
- [3] Rufli T, Lehner S, Aeschlimann A, Chamot E, Gigon F, Jeanneret JP. Enlarged spectrum of tick transmitted spirochaetoses. *Hautarzt* 1986; 37(11): 597-602. [PMID: 3804731]
- [4] Weide B, Walz T, Garbe C. Is morphea caused by *Borrelia burgdorferi*? A review. *Br J Dermatol* 2000; 142(4): 636-44. [http://dx.doi.org/10.1046/j.1365-2133.2000.03407.x] [PMID: 10792212]

- [5] Ozkan S, Atabey N, Fetil E, Erkizan V, Günes AT. Evidence for *Borrelia burgdorferi* in morphea and lichen sclerosus. *Int J Dermatol* 2000; 39(4): 278-83. [http://dx.doi.org/10.1046/j.1365-4362.2000.00912.x] [PMID: 10809977]
- [6] Zollinger T, Mertz KD, Schmid M, Schmitt A, Pfaltz M, Kempf W. *Borrelia* in granuloma annulare, morphea and lichen sclerosus: a PCR-based study and review of the literature. *J Cutan Pathol* 2010; 37(5): 571-7. [http://dx.doi.org/10.1111/j.1600-0560.2009.01493.x] [PMID: 20015188]
- [7] Asbrink E. Cutaneous manifestations of Lyme borreliosis. Clinical definitions and differential diagnoses. *Scand J Infect Dis Suppl* 1991; 77: 44-50. [PMID: 1947811]
- [8] Marsch WC, Mayet A, Wolter M. Cutaneous fibroses induced by *Borrelia burgdorferi*. *Br J Dermatol* 1993; 128(6): 674-8. [http://dx.doi.org/10.1111/j.1365-2133.1993.tb00264.x] [PMID: 8338751]
- [9] Büchner SA, Ruffli T. Morphaea profunda. *Hautarzt* 1990; 41(3): 155-7. [PMID: 2188936]
- [10] Langer K, Diem E. Acrodermatitis chronica atrophicans and sclerodermiform skin changes in *Borrelia* infection. *Hautarzt* 1988; 39(10): 647-51. [PMID: 3235338]
- [11] Coulson IH, Smith NP, Holden CA. Acrodermatitis chronica atrophicans with coexisting morphoea. *Br J Dermatol* 1989; 121(2): 263-9. [http://dx.doi.org/10.1111/j.1365-2133.1989.tb01809.x] [PMID: 2775650]
- [12] Müller H. Acrodermatitis atrophicans arthropathica with pseudoscleroderma, circumscribed scleroderma and muscular involvement. *Z Haut Geschlechtskr* 1969; 44(1): 1-12. [PMID: 5360164]
- [13] Carlesimo M, Abruzzese C, Narcisi A, *et al.* Acrodermatitis chronica atrophicans and morphea. *Eur J Dermatol* 2010; 20(3): 405-7. [PMID: 20299311]
- [14] Ramelet AA. Association of acrodermatitis chronica atrophicans and morphea. *Dermatologica* 1987; 175(5): 253-6. [http://dx.doi.org/10.1159/000248914] [PMID: 3678554]
- [15] Buechner SA, Winkelmann RK, Lautenschlager S, Gilli L, Ruffli T. Localized scleroderma associated with *Borrelia burgdorferi* infection. Clinical, histologic, and immunohistochemical observations. *J Am Acad Dermatol* 1993; 29(2 Pt 1): 190-6. [http://dx.doi.org/10.1016/0190-9622(93)70166-Q] [PMID: 8335737]
- [16] Trevisan G, Rees DH, Stinco G. *Borrelia burgdorferi* and localized scleroderma. *Clin Dermatol* 1994; 12(3): 475-9. [http://dx.doi.org/10.1016/0738-081X(94)90300-X] [PMID: 7954205]
- [17] Aberer E, Neumann R, Lubec G. Acrodermatitis chronica atrophicans in association with lichen sclerosus et atrophicans: tubulo-interstitial nephritis and urinary excretion of spirochete-like organisms. *Acta Derm Venereol* 1987; 67(1): 62-5. [PMID: 2436416]
- [18] Kreuter A, Krieg T, Worm M, *et al.* AWMF Guideline no. 013/066. Diagnosis and therapy of circumscribed scleroderma. *J Dtsch Dermatol Ges* 2009; 7(Suppl. 6): S1-S14. [PMID: 19660073]
- [19] Classification of circumscribed scleroderma. A multicenter study of 286 patients. The Scleroderma Study Group of the Society of Dermatologic Research. *Hautarzt* 1990; 41: 16-21.
- [20] Serup J. Localized scleroderma (morphoea). Clinical, physiological, biochemical and ultrastructural studies with particular reference to quantitation of scleroderma. *Acta Derm Venereol Suppl (Stockh)* 1986; 122: 3-61. [PMID: 2939680]
- [21] Badakov S. Elastoid transformation of the collagen fibrils in scleroderma skin. *Folia Med (Plovdiv)* 1992; 34(3-4): 17-21. [PMID: 1369506]
- [22] Brehmer-Andersson E, Hovmark A, Asbrink E. Acrodermatitis chronica atrophicans: histopathologic findings and clinical correlations in 111 cases. *Acta Derm Venereol* 1998; 78(3): 207-13. [http://dx.doi.org/10.1080/000155598441558] [PMID: 9602229]
- [23] de Koning J, Tazelaar DJ, Hoogkamp-Korstanje JA, Elema JD. Acrodermatitis chronica atrophicans: a light and electron microscopic study. *J Cutan Pathol* 1995; 22(1): 23-32. [http://dx.doi.org/10.1111/j.1600-0560.1995.tb00735.x] [PMID: 7751475]
- [24] Aberer E, Klade H, Hobisch G. A clinical, histological, and immunohistochemical comparison of acrodermatitis chronica atrophicans and morphea. *Am J Dermatopathol* 1991; 13(4): 334-41. [http://dx.doi.org/10.1097/00000372-199108000-00003] [PMID: 1928618]
- [25] Aberer E, Klade H, Stanek G, Gebhart W. *Borrelia burgdorferi* and different types of morphea. *Dermatologica* 1991; 182(3): 145-54. [http://dx.doi.org/10.1159/000247767] [PMID: 1879581]
- [26] Shiba Y, Ono K, Akiyama M, Fujimoto N, Tajima S. Increase of elastic fibers in lichen sclerosus et atrophicus. *J Cutan Pathol* 2014; 41(8): 646-9.

- [http://dx.doi.org/10.1111/cup.12342] [PMID: 24641179]
- [27] Frances C, Wechsler J, Meimon G, Labat-Robert J, Grimaud JA, Hewitt J. Investigation of intercellular matrix macromolecules involved in lichen sclerosis. *Acta Derm Venereol* 1983; 63(6): 483-90. [PMID: 6198836]
- [28] Mihara Y, Mihara M, Hagari Y, Shimao S. Lichen sclerosis et atrophicus. A histological, immunohistochemical and electron microscopic study. *Arch Dermatol Res* 1994; 286(8): 434-42. [http://dx.doi.org/10.1007/BF00371568] [PMID: 7864656]
- [29] Kreuter A, Wischniewski J, Terras S, Altmeyer P, Stücker M, Gambichler T. Coexistence of lichen sclerosis and morphea: a retrospective analysis of 472 patients with localized scleroderma from a German tertiary referral center. *J Am Acad Dermatol* 2012; 67(6): 1157-62. [http://dx.doi.org/10.1016/j.jaad.2012.04.003] [PMID: 22533994]
- [30] Aberer E, Stanek G, Ertl M, Neumann R. Evidence for spirochetal origin of circumscribed scleroderma (morphea). *Acta Derm Venereol* 1987; 67(3): 225-31. [PMID: 2442935]
- [31] Aberer E, Kollegger H, Kristoferitsch W, Stanek G. Neuroborreliosis in morphea and lichen sclerosis et atrophicus. *J Am Acad Dermatol* 1988; 19(5 Pt 1): 820-5. [http://dx.doi.org/10.1016/S0190-9622(88)70239-X] [PMID: 3192771]
- [32] Buechner SA, Ruffli T. Atrophoderma of Pasini and Pierini. Clinical and histopathologic findings and antibodies to *Borrelia burgdorferi* in thirty-four patients. *J Am Acad Dermatol* 1994; 30(3): 441-6. [http://dx.doi.org/10.1016/S0190-9622(94)70053-2] [PMID: 8113457]
- [33] Wienecke R, Schlüpen EM, Zöchling N, Neubert U, Meurer M, Volkenandt M. No evidence for *Borrelia burgdorferi*-specific DNA in lesions of localized scleroderma. *J Invest Dermatol* 1995; 104(1): 23-6. [http://dx.doi.org/10.1111/1523-1747.ep12613456] [PMID: 7798636]
- [34] Buechner SA, Lautenschlager S, Itin P, Bircher A, Erb P. Lymphoproliferative responses to *Borrelia burgdorferi* in patients with erythema migrans, acrodermatitis chronica atrophicans, lymphadenosis benigna cutis, and morphea. *Arch Dermatol* 1995; 131(6): 673-7. [http://dx.doi.org/10.1001/archderm.1995.01690180047008] [PMID: 7778918]
- [35] Kencka D, Blaszczyk M, Jabłońska S. Atrophoderma Pasini-Pierini is a primary atrophic abortive morphea. *Dermatology (Basel)* 1995; 190(3): 203-6. [http://dx.doi.org/10.1159/000246685] [PMID: 7599381]
- [36] Breier P, Klade H, Stanek G, *et al*. Lymphoproliferative responses to *Borrelia burgdorferi* in circumscribed scleroderma. *Br J Dermatol* 1996; 134(2): 285-91. [http://dx.doi.org/10.1111/j.1365-2133.1996.tb07615.x] [PMID: 8746343]
- [37] Trevisan G. Detection of *Borrelia burgdorferi* in skin biopsies from patients with morphea by polymerase chain reaction. *J Eur Acad Dermatol Venereol* 1996; 6: 15-9. [http://dx.doi.org/10.1111/j.1468-3083.1996.tb00127.x] [PMID: 8746343]
- [38] Svecova D, Buchvald J. *Borrelia burgdorferi* antibodies in scleroderma circumscripta, lichen sclerosis et atrophicus, erythema nodosum, granuloma annulare, erythema annulare and chronic urticaria. *Bratisl Lek Listy (Tlacene Vyd)* 2000; 101(4): 194-9. [PMID: 10914463]
- [39] Wojas-Pelc A, Wielowieyska-Szybińska D, Kiełtyka A. Presence of the antinuclear antibodies and antibodies to *Borrelia burgdorferi* among patients with morphea en plaque, deep linear scleroderma and atrophoderma Pasini-Pierini. *Przegl Lek* 2002; 59(11): 898-902. [PMID: 12715718]
- [40] Prinz JC, Kutasi Z, Weisenseel P, Pótó L, Battyáni Z, Ruzicka T. "Borrelia-associated early-onset morphea": a particular type of scleroderma in childhood and adolescence with high titer antinuclear antibodies? Results of a cohort analysis and presentation of three cases. *J Am Acad Dermatol* 2009; 60(2): 248-55. [http://dx.doi.org/10.1016/j.jaad.2008.09.023] [PMID: 19022534]
- [41] Muhlemann MF, Wright DJ, Black C. Serology of Lyme disease. *Lancet* 1986; 1(8480): 553-4. [http://dx.doi.org/10.1016/S0140-6736(86)90903-7] [PMID: 2869276]
- [42] Hansen K, Serup J, Høybye S. Antibodies to *Borrelia burgdorferi* and localised scleroderma. *Lancet* 1987; 1(8534): 682. [http://dx.doi.org/10.1016/S0140-6736(87)90441-7] [PMID: 2882098]
- [43] Lecerf V, Bagot M, Revuz J, Touraine R, Dournon E. *Borrelia burgdorferi* and localized scleroderma. *Arch Dermatol* 1989; 125(2): 297. [http://dx.doi.org/10.1001/archderm.1989.01670140149031] [PMID: 2913967]
- [44] Lecerf V, Bagot M, Dournon E, Cosnes A, Touraine R, Revuz J. Negativity of *Borrelia burgdorferi* serology in scleroderma en plaques. *Ann Dermatol Venereol* 1989; 116(8): 539-42. [PMID: 2688515]
- [45] Halkier-Sørensen L, Kragballe K, Hansen K. Antibodies to the *Borrelia burgdorferi* flagellum in patients with scleroderma, granuloma annulare and porphyria cutanea tarda. *Acta Derm Venereol* 1989; 69(2): 116-9. [PMID: 2564227]
- [46] Vaillant L, Goudeau A. Localized scleroderma is not a *Borrelia burgdorferi* infection in France. *Dermatology (Basel)* 1992; 184(4): 286-8.

- [http://dx.doi.org/10.1159/000247569] [PMID: 1498396]
- [47] Raguin G, Boissic S, Souteyrand P, *et al*. No evidence for a spirochaetal origin of localized scleroderma. *Br J Dermatol* 1992; 127(3): 218-20. [http://dx.doi.org/10.1111/j.1365-2133.1992.tb00117.x] [PMID: 1390164]
- [48] Schempp C, Bocklage H, Lange R, Kölmel HW, Orfanos CE, Gollnick H. Further evidence for *Borrelia burgdorferi* infection in morphea and lichen sclerosus et atrophicus confirmed by DNA amplification. *J Invest Dermatol* 1993; 100(5): 717-20. [http://dx.doi.org/10.1111/1523-1747.ep12472369] [PMID: 8491994]
- [49] Meis JF, Koopman R, van Bergen B, Pool G, Melchers W. No evidence for a relation between *Borrelia burgdorferi* infection and old lesions of localized scleroderma (morphea). *Arch Dermatol* 1993; 129(3): 386-7. [http://dx.doi.org/10.1001/archderm.1993.01680240132029] [PMID: 8447688]
- [50] Ranki A, Aavik E, Peterson P, Schauman K, Nurmilaakso P. Successful amplification of DNA specific for Finnish *Borrelia burgdorferi* isolates in erythema chronicum migrans but not in circumscribed scleroderma lesions. *J Invest Dermatol* 1994; 102(3): 339-45. [http://dx.doi.org/10.1111/1523-1747.ep12371793] [PMID: 8120417]
- [51] Fan W, Leonardi CL, Penneys NS. Absence of *Borrelia burgdorferi* in patients with localized scleroderma (morphea). *J Am Acad Dermatol* 1995; 33(4): 682-4. [http://dx.doi.org/10.1016/0190-9622(95)91311-4] [PMID: 7673508]
- [52] Akimoto S, Ishikawa O, Miyachi Y. The absence of antibodies against *Borrelia burgdorferi* in the sera of Japanese patients with localized scleroderma. *J Rheumatol* 1996; 23(3): 573-4. [PMID: 8833012]
- [53] Alonso-Llamazares J, Persing DH, Anda P, Gibson LE, Rutledge BJ, Iglesias L. No evidence for *Borrelia burgdorferi* infection in lesions of morphea and lichen sclerosus et atrophicus in Spain. A prospective study and literature review. *Acta Derm Venereol* 1997; 77(4): 299-304. [PMID: 9228224]
- [54] Sommer A, Gambichler T, Bacharach-Buhles M, von Rothenburg T, Altmeyer P, Kreuter A. Clinical and serological characteristics of progressive facial hemiatrophy: a case series of 12 patients. *J Am Acad Dermatol* 2006; 54(2): 227-33. [http://dx.doi.org/10.1016/j.jaad.2005.10.020] [PMID: 16443052]
- [55] Espinoza-León F, Hassanhi-Hassanhi M, Arocha-Sandoval F, Urbina-López M. Absence of *Borrelia burgdorferi* antibodies in the sera of Venezuelan patients with localized scleroderma (morphea). *Invest Clin* 2006; 47(3): 283-8. [PMID: 17672287]
- [56] Aberer E, Stanek G. Histological evidence for spirochaetal origin of morphea and lichen sclerosus et atrophicus. *Am J Dermatopathol* 1987; 9(5): 374-9. [http://dx.doi.org/10.1097/00000372-198710000-00002] [PMID: 3318532]
- [57] Aberer E, Kersten A, Klade H, Poitschek C, Jurecka W. Heterogeneity of *Borrelia burgdorferi* in the skin. *Am J Dermatopathol* 1996; 18(6): 571-9. [http://dx.doi.org/10.1097/00000372-199612000-00004] [PMID: 8989928]
- [58] Ross SA, Sánchez JL, Taboas JO. Spirochaetal forms in the dermal lesions of morphea and lichen sclerosus et atrophicus. *Am J Dermatopathol* 1990; 12(4): 357-62. [http://dx.doi.org/10.1097/00000372-199008000-00005] [PMID: 2393064]
- [59] Eisendle K, Grabner T, Zelger B. Morphoea: a manifestation of infection with *Borrelia* species? *Br J Dermatol* 2007; 157(6): 1189-98. [http://dx.doi.org/10.1111/j.1365-2133.2007.08235.x] [PMID: 17941947]
- [60] Santos M, Ribeiro-Rodrigues R, Talhari C, Ferreira LC, Zelger B, Talhari S. Presence of *Borrelia burgdorferi* "Sensu Lato" in patients with morphea from the Amazonic region in Brazil. *Int J Dermatol* 2011; 50(11): 1373-8. [http://dx.doi.org/10.1111/j.1365-4632.2011.05081.x] [PMID: 22004491]
- [61] Verberkt RM, Janssen M, Wesseling J. A boy with a tight skin: *Borrelia*-associated early-onset morphea. *Clin Exp Rheumatol* 2014; 32(1): 121-2. [PMID: 24093617]
- [62] Daoud MS, Su WP, Leiferman KM, Perniciaro C. Bullous morphea: clinical, pathologic, and immunopathologic evaluation of thirteen cases. *J Am Acad Dermatol* 1994; 30(6): 937-43. [http://dx.doi.org/10.1016/S0190-9622(94)70113-X] [PMID: 8188883]
- [63] Fujiwara H, Fujiwara K, Hashimoto K, *et al*. Detection of *Borrelia burgdorferi* DNA (*B garinii* or *B afzelii*) in morphea and lichen sclerosus et atrophicus tissues of German and Japanese but not of US patients. *Arch Dermatol* 1997; 133(1): 41-4. [http://dx.doi.org/10.1001/archderm.1997.03890370047008] [PMID: 9006371]
- [64] Hercogova J. *Borrelia burgdorferi*: a protagonist in Lyme disease, a bystander in morphoea? *J Eur Acad Dermatol Venereol* 2002; 16(2): 98-9. [http://dx.doi.org/10.1046/j.1468-3083.2002.00321.x] [PMID: 12046842]
- [65] Weidenthaler B, Roux M, Moter SE, Schulze HJ, Kramer MD. Sclerodermiform skin changes in *Borrelia burgdorferi* infection. Diagnostic use of polymerase chain reaction. *Hautarzt* 1994; 45(3): 171-5. [http://dx.doi.org/10.1007/s001050050058] [PMID: 8175346]
- [66] Dillon WI, Saed GM, Fivenson DP. *Borrelia burgdorferi* DNA is undetectable by polymerase chain reaction in skin lesions of morphea, scleroderma, or lichen sclerosus et atrophicus of patients from North America. *J Am Acad Dermatol* 1995; 33(4): 617-20.



- [http://dx.doi.org/10.1016/0190-9622(95)91281-9] [PMID: 7673495]
- [67] De Vito JR, Merogi AJ, Vo T, *et al.* Role of *Borrelia burgdorferi* in the pathogenesis of morphea/scleroderma and lichen sclerosus et atrophicus: a PCR study of thirty-five cases. *J Cutan Pathol* 1996; 23(4): 350-8.  
[http://dx.doi.org/10.1111/j.1600-0560.1996.tb01309.x] [PMID: 8864923]
- [68] Colomé-Grimmer MI, Payne DA, Tyring SK, Sánchez RL. *Borrelia burgdorferi* DNA and *Borrelia hermsii* DNA are not associated with morphea or lichen sclerosus et atrophicus in the southwestern United States. *Arch Dermatol* 1997; 133(9): 1174.  
[http://dx.doi.org/10.1001/archderm.133.9.1174] [PMID: 9301604]
- [69] Espinoza-León F, Arocha F, Hassanhi M, Arévalo J. Using the polymerase chain reaction to *Borrelia burgdorferi* infection in localized scleroderma injure (morphea), in Venezuelan patients. *Invest Clin* 2010; 51(3): 381-90.  
[PMID: 21305774]
- [70] Weber K, Preac-Mursic V, Reimers CD. Spirochetes isolated from two patients with morphea. *Infection* 1988; 16(1): 25-6.  
[http://dx.doi.org/10.1007/BF01646925] [PMID: 3360493]
- [71] Breier FH, Aberer E, Stanek G, Khanakaha G, Schlick A, Tappeiner G. Isolation of *Borrelia afzelii* from circumscribed scleroderma. *Br J Dermatol* 1999; 140(5): 925-30.  
[http://dx.doi.org/10.1046/j.1365-2133.1999.02828.x] [PMID: 10354035]
- [72] Schempp C, Bocklage H, Owsianowski M, Lange R, Orfanos CE, Gollnick H. In vivo and in vitro detection of borrelia infection in morphea-like skin changes with negative *Borrelia* serology. *Hautarzt* 1993; 44(1): 14-8.  
[PMID: 8436502]
- [73] Mosconi S, Streit M, Brönimann M, Braathen L. Eosinophilic fasciitis (Shulman syndrome). *Dermatology (Basel)* 2002; 205(2): 204-6.  
[http://dx.doi.org/10.1159/000063916] [PMID: 12218249]
- [74] Stanek G, Konrad K, Jung M, Ehringer H. Shulman syndrome, a scleroderma subtype caused by *Borrelia burgdorferi*? *Lancet* 1987; 1(8548): 1490.  
[http://dx.doi.org/10.1016/S0140-6736(87)92235-5] [PMID: 2885476]
- [75] Hirai K, Takemori N, Yanagawa N, Namiki M, Iizuka H, Miyamoto K. *Borrelia burgdorferi* and Shulman syndrome. *Lancet* 1992; 340(8833): 1472.  
[http://dx.doi.org/10.1016/0140-6736(92)92663-Z] [PMID: 1360588]
- [76] Belot V, Mulleman D, Perrinaud A, Abdallah-Lotf M, Machet MC, Machet L. Eosinophilic fasciitis associated with *Borrelia burgdorferi* infection. *Ann Dermatol Venereol* 2007; 134(8-9): 673-7.  
[http://dx.doi.org/10.1016/S0151-9638(07)91831-1] [PMID: 17925693]
- [77] Sepp N, Schmutzhard E, Fritsch P. Shulman syndrome associated with *Borrelia burgdorferi* and complicated by carpal tunnel syndrome. *J Am Acad Dermatol* 1988; 18(6): 1361-2.  
[http://dx.doi.org/10.1016/S0190-9622(88)80117-8] [PMID: 3385049]
- [78] Ferradini L, Bagot M, Roujeau JC, Touraine R. *Borrelia burgdorferi* and Shulman syndrome. *Lancet* 1987; 2(8559): 624.  
[http://dx.doi.org/10.1016/S0140-6736(87)93010-8] [PMID: 2887905]
- [79] Hashimoto Y, Takahashi H, Matsuo S, *et al.* Polymerase chain reaction of *Borrelia burgdorferi* flagellin gene in Shulman syndrome. *Dermatology (Basel)* 1996; 192(2): 136-9.  
[http://dx.doi.org/10.1159/000246339] [PMID: 8829496]
- [80] Granter SR, Barnhill RL, Duray PH. Borrelial fasciitis: diffuse fasciitis and peripheral eosinophilia associated with *Borrelia* infection. *Am J Dermatopathol* 1996; 18(5): 465-73.  
[http://dx.doi.org/10.1097/00000372-199610000-00004] [PMID: 8902092]
- [81] Stern HS, Elliott LF, Beegle PH Jr. Progressive hemifacial atrophy associated with Lyme disease. *Plast Reconstr Surg* 1992; 90(3): 479-83.  
[http://dx.doi.org/10.1097/00006534-199209000-00020] [PMID: 1513894]
- [82] Baskan EB, Kaçar SD, Turan A, Saricaoglu H, Tunali S, Adim SB. Parry-Romberg syndrome associated with borreliosis: could photochemotherapy halt the progression of the disease? *Photodermatol Photoimmunol Photomed* 2006; 22(5): 259-61.  
[http://dx.doi.org/10.1111/j.1600-0781.2006.00238.x] [PMID: 16948828]
- [83] Sahin MT, Barış S, Karaman A. Parry-Romberg syndrome: a possible association with borreliosis. *J Eur Acad Dermatol Venereol* 2004; 18(2): 204-7.  
[http://dx.doi.org/10.1111/j.1468-3083.2004.00862.x] [PMID: 15009307]
- [84] Salpietro DC, Merlino MV, Bruglia S, Guarneri F, Vaccaro M. Linear scleroderma 'en coup de sabre' associated with facial atrophy in a patient seropositive for *Borrelia burgdorferi*: a true case of molecular mimicry? *Pediatr Allergy Immunol* 2004; 15(6): 570-2.  
[http://dx.doi.org/10.1111/j.1399-3038.2004.00189.x] [PMID: 15610374]
- [85] Eisendle K, Grabner T, Kutzner H, Zelger B. Possible role of *Borrelia burgdorferi* sensu lato infection in lichen sclerosus. *Arch Dermatol* 2008; 144(5): 591-8.  
[http://dx.doi.org/10.1001/archderm.144.5.591] [PMID: 18490585]
- [86] Aberer E, Schmidt BL, Breier F, Kinaciyan T, Luger A. Amplification of DNA of *Borrelia burgdorferi* in urine samples of patients with granuloma annulare and lichen sclerosus et atrophicus. *Arch Dermatol* 1999; 135(2): 210-2.  
[http://dx.doi.org/10.1001/archderm.135.2.210] [PMID: 10052416]

- [87] Trevisan G, Padovan C, Scaini MT, Cinco M, Floris R, Bonin S. Anetoderma associated with Lyme disease: a case report. *Acta Derm Venereol* 2008; 88(5): 536-8. [http://dx.doi.org/10.2340/00015555-0513] [PMID: 18779908]
- [88] Strunk T, Hetzer S, Homey B, Reifemberger J. Anetoderma with positive Borrelia serology. *Hautarzt* 2011; 62(10): 720-2. [http://dx.doi.org/10.1007/s00105-011-2240-8] [PMID: 21915730]
- [89] Hofer T, Goldenberger D, Itin PH. Anetoderma and borreliosis: is there a pathogenetic relationship? *Eur J Dermatol* 2003; 13(4): 399-401. [PMID: 12948924]
- [90] Bauer J, Leitz G, Palmedo G, Hügel H. Anetoderma: another facet of Lyme disease? *J Am Acad Dermatol* 2003; 48(5)(Suppl.): S86-8. [http://dx.doi.org/10.1067/mjd.2003.165] [PMID: 12734487]
- [91] Aberer E, Weissenbacher G. Congenital anetoderma induced by intrauterine infection? *Arch Dermatol* 1997; 133(4): 526-7. [http://dx.doi.org/10.1001/archderm.1997.03890400132021] [PMID: 9126031]
- [92] Wackernagel A, Bergmann AR, Aberer E. Acute exacerbation of systemic scleroderma in Borrelia burgdorferi infection. *J Eur Acad Dermatol Venereol* 2005; 19(1): 93-6. [http://dx.doi.org/10.1111/j.1468-3083.2004.01074.x] [PMID: 15649200]
- [93] Gubertini N, Bonin S, Trevisan G. Lichen sclerosus et atrophicans, scleroderma en coup de sabre and Lyme borreliosis. *Dermatol Rep* 2011; 3(2): e27. [http://dx.doi.org/10.4081/dr.2011.e27] [PMID: 25386279]
- [94] Shelley WB, Shelley ED, Amurao CV. Treatment of lichen sclerosus with antibiotics. *Int J Dermatol* 2006; 45(9): 1104-6. [http://dx.doi.org/10.1111/j.1365-4632.2006.02978.x] [PMID: 16961523]
- [95] Miglino B, Viana M, Zavattaro E, Bonin S, Valente G, Colombo E. Localized scleroderma unius lateri and Borrelia burgdorferi infection. *Indian J Dermatol Venereol Leprol* 2012; 78(3): 383-5. [http://dx.doi.org/10.4103/0378-6323.95460] [PMID: 22565449]
- [96] Buechner SA, Ruffli T, Erb P. Acrodermatitis chronic atrophicans: a chronic T-cell-mediated immune reaction against Borrelia burgdorferi? Clinical, histologic, and immunohistochemical study of five cases. *J Am Acad Dermatol* 1993; 28(3): 399-405. [http://dx.doi.org/10.1016/0190-9622(93)70058-2] [PMID: 8095272]
- [97] Cadavid D, Bai Y, Hodzic E, Narayan K, Barthold SW, Pachner AR. Cardiac involvement in non-human primates infected with the Lyme disease spirochete Borrelia burgdorferi. *Lab Invest* 2004; 84(11): 1439-50. [http://dx.doi.org/10.1038/labinvest.3700177] [PMID: 15448708]
- [98] Zambrano MC, Beklemisheva AA, Bryksin AV, Newman SA, Cabello FC. Borrelia burgdorferi binds to, invades, and colonizes native type I collagen lattices. *Infect Immun* 2004; 72(6): 3138-46. [http://dx.doi.org/10.1128/IAI.72.6.3138-3146.2004] [PMID: 15155615]
- [99] Cabello FC, Godfrey HP, Newman SA. Hidden in plain sight: Borrelia burgdorferi and the extracellular matrix. *Trends Microbiol* 2007; 15(8): 350-4. [http://dx.doi.org/10.1016/j.tim.2007.06.003] [PMID: 17600717]
- [100] Parveen N, Leong JM. Identification of a candidate glycosaminoglycan-binding adhesin of the Lyme disease spirochete Borrelia burgdorferi. *Mol Microbiol* 2000; 35(5): 1220-34. [http://dx.doi.org/10.1046/j.1365-2958.2000.01792.x] [PMID: 10712702]
- [101] Jiménez SA, Artlett CM, Sandorfi N, et al. Dialysis-associated systemic fibrosis (nephrogenic fibrosing dermopathy): study of inflammatory cells and transforming growth factor beta1 expression in affected skin. *Arthritis Rheum* 2004; 50(8): 2660-6. [http://dx.doi.org/10.1002/art.20362] [PMID: 15334482]
- [102] Brissette CA, Bykowski T, Cooley AE, Bowman A, Stevenson B. Borrelia burgdorferi RevA antigen binds host fibronectin. *Infect Immun* 2009; 77(7): 2802-12. [http://dx.doi.org/10.1128/IAI.00227-09] [PMID: 19398540]
- [103] Liang FT, Brown EL, Wang T, Iozzo RV, Fikrig E. Protective niche for Borrelia burgdorferi to evade humoral immunity. *Am J Pathol* 2004; 165(3): 977-85. [http://dx.doi.org/10.1016/S0002-9440(10)63359-7] [PMID: 15331421]
- [104] Grab DJ, Kennedy R, Philipp MT. Borrelia burgdorferi possesses a collagenolytic activity. *FEMS Microbiol Lett* 1996; 144(1): 39-45. [http://dx.doi.org/10.1111/j.1574-6968.1996.tb08506.x] [PMID: 8870250]
- [105] Coleman JL, Roemer EJ, Benach JL. Plasmin-coated borrelia Burgdorferi degrades soluble and insoluble components of the mammalian extracellular matrix. *Infect Immun* 1999; 67(8): 3929-36. [PMID: 10417158]
- [106] Ackerman AB. Fibrosing Dermatitis. In: *Histologic Diagnosis of inflammatory skin diseases*. Philadelphia: Lea & Febinger, Henry Kimpton Publishers 1978; p. 715.
- [107] Müller KE. Damage of collagen and elastic fibres by borrelia burgdorferi-known and new clinical and histopathological aspects. *Open Neurol J* 2012; 6: 179-86. [http://dx.doi.org/10.2174/1874205X01206010179] [PMID: 23986790]

- [108] Weber K. Is juvenile localized scleroderma related to Lyme borreliosis? *J Am Acad Dermatol* 2009; 61(5): 901. [http://dx.doi.org/10.1016/j.jaad.2009.05.022] [PMID: 19836648]
- [109] Hoesly JM, Mertz LE, Winkelmann RK. Localized scleroderma (morphea) and antibody to *Borrelia burgdorferi*. *J Am Acad Dermatol* 1987; 17(3): 455-8. [http://dx.doi.org/10.1016/S0190-9622(87)70229-1] [PMID: 3308981]
- [110] Eisendle K, Zelger B. The expanding spectrum of cutaneous borreliosis. *G Ital Dermatol Venereol* 2009; 144(2): 157-71. [PMID: 19357623]
- [111] Aberer E, Dekan G, Mayr Kanhäuser S, Aberer W. Extravascular necrotizing granuloma induced by mineral wool in circumscribed scleroderma lesions. *Exogenous Dermatol* 2002; 1: 253-9. [http://dx.doi.org/10.1159/000068800]
- [112] Trevisan G, Padovan C, Scaini MT, Cinco M, Floris R, Bonin S. Anetoderma associated with lyme disease: a case report. *Acta Derm Venereol* 2008; 88(5): 536-8. [http://dx.doi.org/10.2340/00015555-0513] [PMID: 18779908]
- [113] Kaya G, Berset M, Prins C, Chavaz P, Saurat JH. Chronic borreliosis presenting with morphea-and lichen sclerosus et atrophicus-like cutaneous lesions. a case report. *Dermatology (Basel)* 2001; 202(4): 373-5. [http://dx.doi.org/10.1159/000051687] [PMID: 11455165]
- [114] Anderegg U, Wilczek A, Hausteil UF. Penicillin G does not alter collagen type I metabolism of dermal fibroblasts in culture. *Dermatology (Basel)* 2000; 200(2): 111-4. [http://dx.doi.org/10.1159/000018341] [PMID: 10773697]

---

Received: October 22, 2015

Revised: December 16, 2015

Accepted: December 16, 2015

© Aberer & Wutte; Licensee *Bentham Open*.

This is an open access article licensed under the terms of the Creative Commons Attribution-Non-Commercial 4.0 International Public License (CC BY-NC 4.0) (<https://creativecommons.org/licenses/by-nc/4.0/legalcode>), which permits unrestricted, non-commercial use, distribution and reproduction in any medium, provided the work is properly cited.