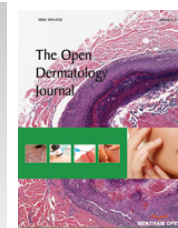




# The Open Dermatology Journal

Content list available at: [www.benthamopen.com/TODJ/](http://www.benthamopen.com/TODJ/)

DOI: 10.2174/1874372201711010012



## REVIEW ARTICLE

# Assessment of Dietary Supplementation in the Treatment of Vitiligo

Mallory K. Smith<sup>1</sup>, Tasneem F. Mohammad<sup>2</sup> and Iltefat H. Hamzavi<sup>2,\*</sup>

<sup>1</sup>Wayne State University School of Medicine, Detroit, MI, USA

<sup>2</sup>Department of Dermatology, Henry Ford Hospital, Detroit, MI, USA

Received: December 14, 2016

Revised: February 01, 2017

Accepted: February 03, 2017

### Abstract:

#### Background:

Vitiligo is the most common acquired pigmentary disorder in the world. Due to alterations in physical appearance, vitiligo is a psychologically devastating disease. Although treatment options exist, a cure for this disease has yet to be discovered. Of recent interest in vitiligo is the relationship between diet and disease.

#### Objective:

To review various dietary modifications and supplementation used in the management of vitiligo.

#### Materials and Methods:

A thorough evaluation of recent literature using the keywords “vitiligo, diet, supplement, antioxidant, vitamin, mineral, zinc, copper, gluten-free, celiac disease, alternative medicine” in the NCBI PubMed search function was performed.

#### Results:

A total of 39 relevant articles were reviewed and critically evaluated.

#### Conclusion:

Initial studies regarding the treatment of vitiligo through dietary modification are promising, although further studies are needed in multiple populations to explore the therapeutic value of these interventions.

**Keywords:** Diet, Vitiligo, Supplementation, Antioxidant, Repigmentation, Management.

## I. INTRODUCTION

Vitiligo is the most common acquired pigmentary disorder, with an estimated prevalence of 1% worldwide [1]. The disease is characterized by the development of depigmented macules and patches due to the loss of functioning melanocytes [2, 3]. Vitiligo is classified into two broad categories, segmental and non-segmental, with the latter being more common. Segmental vitiligo lesions are generally stable, unilateral, and present in a localized or dermatomal distribution. Non-segmental vitiligo is classically characterized by a waxing and waning course with depigmentation in a symmetric, bilateral pattern, and includes the generalized, acrofacial, and universal variants [4]. The pathogenesis of the disease has yet to be fully elucidated, although an impaired response to oxidative stress, autoimmunity, inflammatory, and neurogenic components may all play a role [2, 4]. The association between vitiligo and other autoimmune diseases, such as thyroid disease, psoriasis, and inflammatory bowel disease has been established, supporting an autoimmune etiology [5]. Other studies have proposed the relationship between free radicals and an

\* Address correspondence to this author at the Department of Dermatology, Henry Ford Health System, 3031 West Grand Boulevard, Suite 800, Detroit, MI 48202, USA; Tel: (313) 916-6964; Email: [ihamzav1@hfhs.org](mailto:ihamzav1@hfhs.org)

impaired response of melanocytes to oxidative stress in the pathogenesis of vitiligo [2, 6].

Although there is no cure, a variety of treatment options exist for patients with vitiligo, each with different mechanisms of repigmentation and varying success. These include topical medications such as corticosteroids or immunomodulators, phototherapy, oral medications, autologous melanocyte or epidermal transplant, surgery, and depigmentation [7]. While these therapies are important components in the treatment of vitiligo, the role of dietary modification and supplementation is often overlooked [1, 8]. Recent studies have shown that alterations in dietary intake and oral supplementation can be beneficial in the treatment of many diseases, including vitiligo. This article aims to review the various types of dietary modifications and supplementation used in the management of vitiligo.

## II. MATERIALS AND METHODS

The literature review process was carried out using the keywords “vitiligo, diet, supplement, antioxidant, vitamin, mineral, zinc, copper, gluten free, celiac disease, alternative medicine” in the NCBI PubMed search function. This review utilized articles published within the past ten to fifteen years to obtain recent information and developments. Each article was critically appraised to determine applicability to the topic at hand.

## III. RESULTS

A total of 44 recent, relevant publications were identified within the scope of this review. Additionally, recent textbooks, as well as USDA and U.S. Department of Health and Human Services online resources were used for reference in the formulation of the discussion and conclusions sections of this article.

## IV. DISCUSSION

### A. Antioxidants

There is evidence to support an imbalance between oxidants and antioxidants in individuals affected by vitiligo. It has been proposed that an overproduction of reactive oxygen species (ROS), in combination with the inherent sensitivity of melanocytes to oxidative stress, may be a mechanism for melanocyte damage and death in vitiligo [9]. Yildirim *et al.* showed that activity levels of oxidative stress markers such as superoxide dismutase (SOD), glutathione peroxidase (GPx), and malondialdehyde (MDA) were significantly elevated in tissue samples of vitiligo patients [10]. SOD and GPx are enzymes involved in the breakdown of ROS, whereas MDA is produced *via* lipid peroxidation, often caused by the accumulation of ROS. Other studies observed significantly elevated serum levels of MDA and significantly lower serum levels of SOD, GPx, Vitamins C and E, and overall antioxidant activity in patients with this disease. Serum antioxidant levels were likely lower due to their use in quenching free radicals, whereas MDA was elevated due to the presence of ROS [11].

Imbalances in ox-redox status in vitiligo led to the use of antioxidant supplementation as adjuvant therapy. Oral supplementation with an antioxidant blend of *Phyllanthus emblica* fruit extracts, vitamin E, and carotenoids, combined with standard topical treatments and/or narrowband ultraviolet B (NBUVB) phototherapy, showed statistically significant increases in repigmentation compared to topical treatment and/or NBUVB alone. Lower levels of serum inflammatory markers were detected in the antioxidant treatment group as well [12].

Alpha-lipoic acid, an over the counter supplement, has also been shown to be beneficial as an adjuvant supplement. This substance acts as a free radical scavenger, lipoxygenase inhibitor, glutathione synthesis promoter, and a factor in the recycling of other antioxidants, such as vitamins C and E [13]. Similarly to the study above, a combination of vitamins C and E, alpha-lipoic acid, and polyunsaturated fats was used as antioxidant supplementation along with NBUVB phototherapy. A statistically significant increase in repigmentation and decrease in serum reactive oxygen species (ROS) was noted compared to NBUVB phototherapy alone [13].

Supplementation with vitamin E, an antioxidant known to prevent lipid peroxidation, has also been used as an adjunct to NBUVB phototherapy. Study results from Elgoweini *et al.* reported 72.7% repigmentation in the vitamin E-NBUVB group (n=12), compared to 55.6% repigmentation in the NBUVB phototherapy group (n=12). In particular, the average number of treatments required to achieve 50% repigmentation was significantly lower in the vitamin E supplementation group than the control group, indicating a more rapid repigmentation with the supplement [14]. Additionally, a significantly lower level of serum MDA was observed in the vitamin E group at the end of the study compared to the beginning, further supporting the value of antioxidant supplementation with traditional phototherapy treatment regimens for vitiligo [14]. Common foods high in vitamin E include sunflower seeds, almonds, hazelnuts,

peanuts, oils from the aforementioned plants, and breakfast cereals [15]. Caution should be observed in using and recommending this supplement, as vitamin E has antiplatelet properties and should be used with care in patients with bleeding diathesis or recent surgical procedures. Additionally, vitamin E is lipid soluble, and overdose is a concern due to the complex metabolism and storage in the body. The recommended daily allowance and upper intake limit for vitamin E is found in Table 5 below.

*Polypodium leucotomos* extract (PLE) is another antioxidant used to treat dermatologic diseases. Derived from a fern native to Central and South America, this over the counter supplement has been used in the management of conditions including photodermatoses, vitiligo, pigmentary disorders, and as a photoprotectant [16]. PLE contains numerous phenolic compounds with potent antioxidant, anti-inflammatory, and photoprotective properties [17 - 19]. The combination of NBUVB and oral PLE provided statistically significant increases in repigmentation in 50 patients with generalized vitiligo, compared to placebo with NBUVB phototherapy alone. The study concluded that 44% of the PLE treated patients experienced repigmentation, compared to 27% in the placebo group. In addition, decreased levels of IL-2, IFN- $\gamma$ , and TNF- $\alpha$  were noted in the PLE group, indicating a downregulating effect on cell-mediated immunity [19]. This highlights the interplay between oxidative stress and autoimmunity in the pathogenesis of vitiligo, as well as the utility of oral PLE in disease management. Other studies have shown efficacy in repigmentation with PLE supplementation as well. Pacifico *et al.* supplemented NBUVB therapy with 480 mg oral *P. leucotomos* daily for 6 months, and reported increased repigmentation in the PLE group compared to phototherapy alone [20]. In addition, Reyes *et al.* studied the use of PLE with Psoralen and ultraviolet A (PUVA) treatment, and found that skin repigmentation was significantly higher in the PLE + PUVA group compared to the placebo + PUVA group [21]. Of note, a study by Nestor *et al.* evaluated the safety of PLE in twenty patients taking 240 mg of PLE daily, and reported an excellent safety profile for this dose range. Gastrointestinal discomfort and pruritus were the most commonly noted side effects [22].

*Ginkgo biloba*, a supplement available over the counter, is another antioxidant used in the treatment of vitiligo. Parsad *et al.* studied the efficacy of *G. biloba* oral supplementation in patients with slowly developing vitiligo lesions. The treatment group took 40 mg of *G. biloba* three times daily for a period of six months. The results indicated that *G. biloba* supplements significantly arrested disease progression compared to placebo, and increased repigmentation with few side effects [23]. A more recent open-label pilot study by Szczurko *et al.* showed significant improvement in Vitiligo Scoring Index (VASI) scores with 60 mg of *G. biloba* twice daily for 12 weeks in a total of 12 patients [24]. Additional studies are needed on a larger scale to replicate these findings and provide a better understanding of the mechanism and application of *G. biloba* in the treatment of vitiligo, although initial findings are promising. Of note to patients and physicians, serious side effects include intracranial hemorrhage and bleeding diathesis, due to the substance's antiplatelet effect. *G. biloba* has also been known to interfere pharmacologically with anticoagulation medications. Clinical judgment and care should be used in the initiation of this treatment option [25].

For pediatric patients and those who do not desire supplementation in the form of a capsule, increased intake of foods with high antioxidant content is reasonable. Top dietary sources of antioxidants, modified by Wu *et al.* and reported by Hamzavi *et al.* are shown below (Table 1) [26, 27]. Although there is limited data correlating antioxidant consumption with health outcomes, these antioxidant-rich foods may be beneficial adjuncts in the treatment of vitiligo.

**Table 1. Top 30 foods ranked according to total antioxidant capacities and serving measurements *in vitro* (C, cooked; g, gram; R, raw. TAC, total antioxidant capacity;  $\mu\text{mol}$  of TE, micromoles of Trolox equivalents;  $\mu\text{mol}$  of TE/g, micromoles of Trolox equivalents per gram) [26].**

Rank	Food name	TAC ( $\mu\text{mol}$ of TE/g)	Serving size (g)	TAC/serving ( $\mu\text{mol}$ of TE)
1	Small red bean	149.21	Half cup (92)	13,727
2	Wild blueberry (lowbush)	92.60	One cup (145)	13,427
3	Red kidney bean	144.13	Half cup (92)	13,259
4	Pinto bean	123.59	Half cup (96)	11,864
5	Cultivated blueberry	62.20	One cup (145)	9019
6	Cranberry	94.56	One cup whole (95)	8983
7	Artichoke (C)	94.09	One cup (84)	7904
8	Blackberry	53.48	One cup (144)	7701

(Table 1) contd.....

Rank	Food name	TAC (umol of TE/g)	Serving size (g)	TAC/serving (umol of TE)
9	Prune	85.78	Half cup (85)	7291
10	Raspberry	49.25	One cup (123)	6058
11	Strawberry	35.77	One cup (166)	5938
12	Red Delicious and Granny Smith apple	42.75	One fruit (138)	5900
13	Pecan	179.40	One oz (28.4)	5095
14	Russet potato	13.23	One potato (369)	4882
15	Sweet cherry	33.61	One cup (145)	4873
16	Plum (black)	73.39	One fruit (66)	4844
17	Black bean	80.40	Half cup (52)	4181
18	Gala apple	28.28	One fruit (138)	3903
19	Walnut	135.41	One oz (28.4)	3846
20	Golden delicious and Fuji apples	26.70	One fruit (138)	3685
21	Deglet Noor dates	38.95	Half cup (89)	3467
22	Avocado (Haas)	19.33	One fruit (173)	3344
23	Pear, Green and Red Anjou cultivars	19.11	One fruit (166)	3172
24	Hazelnut	96.45	One oz (28.4)	2739
25	Raab broccoli (R)	30.84	Fifth bunch (85)	2621
26	Navel orange	18.14	One fruit (140)	2540
27	Fig	33.83	Half cup (5)	2537
28	Raisin	30.37	Half cup (82)	2490
29	Red cabbage (C)	31.46	Half cup (75)	2359
30	Red potato	10.98	One potato (213)	2339

With permission from Hamzavi *et al.* (2016).

## B. Gluten-free Diet

Autoimmune diseases often co-exist with vitiligo, as reported by Gill *et al.* [5]. A relationship between vitiligo and celiac disease has been proposed, although evidence has been controversial and incomplete.

Seyhan *et al.* analyzed children and adolescents with celiac disease, reporting that 9.1% of the patients were also diagnosed with vitiligo [28]. Following this evidence, Seyhan *et al.* observed that in a group of 61 patients with vitiligo (40 adults and 21 children), there was an 18% prevalence of concomitant celiac disease seropositivity, with a positivity of 23% in children and 15% in adults. However, the relationship was not statistically significant [29]. Additional studies of vitiligo and celiac disease have shown a statistically significant relationship between celiac disease autoantibodies in patients with vitiligo, although further evaluation is needed as this topic is highly controversial at this time [30].

Case reports have provided interesting, although limited, information regarding repigmentation of patients with vitiligo upon the initiation of a gluten-free diet. In one case report, a 9-year old child with celiac disease experienced extensive repigmentation over three years following the initiation of a gluten-free diet. Seven years later, with the continuation of the gluten-free diet, the repigmentation was maintained [31]. Another case report indicated that a 22-year old female with acrofacial vitiligo experienced significant repigmentation following the initiation of a gluten-free diet, even though she did not have celiac disease. After numerous topical medications and phototherapy failed to induce repigmentation, the elimination of gluten from her diet, in combination with previously initiated oral dapsone, led to rapid repigmentation, the majority of which occurred in the first month [32].

To manage patients with concomitant celiac disease and vitiligo, a gluten-free diet is recommended for the treatment of the celiac disease, and potential repigmentation of vitiligo. In cases of vitiligo where other treatment options have been exhausted, it may be reasonable to initiate a gluten-free diet.

## C. Minerals: Zinc and Copper

The role of supplementation with minerals, such as Zinc (Zn) and Copper (Cu), is another area of interest in vitiligo, although results are controversial. Zinc is a trace element required for homeostasis, with a variety of roles in growth and development, immunomodulation, wound healing, behavior, and taste. It also plays a role in the protection against free radical damage and oxidant-antioxidant balance, as Zn is a required cofactor for SOD [33]. Copper is also an important

mineral in homeostasis, with a similarly broad listing of roles in the body. Copper is also considered an antioxidant, as it acts as a coenzyme with antioxidant properties. Both Zn and Cu may also be involved in melanogenesis through the catalysis of eumelanin production [34]. Zinc may further contribute, as deficiencies in the Zn- $\alpha$ 2-Glycoprotein (ZAG) have been reported in people with vitiligo. ZAG is involved in melanocyte proliferation and maturation, with decreased ZAG levels leading to melanocyte detachment. Additionally, treatment with topical corticosteroids, which causes repigmentation, has the ability to increase ZAG activity. Finally, ZAG has been linked to chromosome 7, which contains mutations in certain patients with generalized vitiligo [35, 36]. This theory has provided an additional basis for the study of Zn supplementation in patients with vitiligo.

Previous studies, such as that by Shameer *et al.*, evaluated serum Zn levels in vitiligo patients, and found a significant relationship between low Zn levels and patients with the disease compared to controls [33]. A meta-analysis of Chinese vitiligo patients by Zeng *et al.* further explored the relationship between both Zn and Cu levels in this population of patients. Serum Cu and Zn were compared between the control and vitiligo patients, with vitiligo patients having significantly lower serum levels of both Cu and Zn compared to controls [34]. Although both of these studies indicate some relationship between serum Zn levels and vitiligo, other findings have determined no significant difference between Zn levels in vitiligo patients compared to controls, leaving this topic controversial [37].

With respect to treatment using oral Zn, Yaghoobi *et al.* studied a group of 86 patients with vitiligo, half of whom were treated with topical corticosteroid alone, while the other half was treated with topical corticosteroid plus oral zinc sulfate. A greater improvement in repigmentation was observed in the treatment group, although it was not statistically significant. Overall, this work provided evidence that the combination of topical corticosteroid and Zn sulfate supplementation was not superior to topical corticosteroid alone, although a positive correlation was observed [38]. Future studies should be continued with larger sample sizes to further understand this potential relationship, in addition to looking at the role Cu supplementation may play in the treatment of vitiligo. The recommended daily allowance and upper intake limits for Cu and Zn are found in Table 5, as well as foods rich in Cu and Zn in Tables 2 and 3.

**Table 2. Selected foods rich in Copper [15].**

Foods	Measure	Copper, Cu (mg) per measure	% RDA (0.9 mg/day)	% UL (10 mg/day)
Beef variety meats and by-products, cooked	1.0 slice	11.816	1312	118
Lamb liver, cooked	3.0 oz	11.390	1265	114
Lamb variety meats and by-products, cooked	3.0 oz	8.356	928	84
Seaweed, spirulina	1.0 cup	6.832	759	68
Mollusks, oyster, cooked	3.0 oz	4.851	539	49
Beef sweetbread, cooked	3.0 oz	4.335	481	43
Cocoa, dry powder, unsweetened	1 cup	3.258	362	33
Cashew nuts, dry roasted	1.0 cup, halves and whole	3.041	338	30
Sunflower seed kernels, toasted	1.0 cup	2.458	273	25
Buckwheat	1.0 cup	1.870	207	19

**Table 3. Selected foods rich in Zinc [15].**

Foods	Measure	Zinc, Zn (mg) per measure	% RDA (8 mg/day)	% UL (10 mg/day)
Mollusks, oyster, eastern, canned	3.0 oz	77.31	966	773
Beef, bottom sirloin	1.0 roast (690g raw meat)	26.57	332	267
Cereals (ready-to-eat)	0.75-1.0 cup	15.0	188	150
Wheat germ	1.0 cup	14.13	177	141
Turkey breast, cooked	1.0 breast	13.12	164	131
Sesame seed kernels, toasted	1.0 cup	13.09	163	131
Lamb, foreshank, cooked	1.0 piece, cooked	11.38	142	114
Ground Turkey	1.0 lb	10.66	133	107
Crustaceans, crab, cooked	1.0 leg	10.21	127	102
Peanuts, oil roasted	1.0 cup	9.47	118	95

#### D. Vitamin D

Vitamin D plays a variety of roles in the human body, including calcium and bone homeostasis, cell proliferation

and growth, and melanogenesis. It is theorized that vitamin D plays an active role in melanogenesis, as this hormone is synthesized within the skin after exposure to UVB light, and perhaps involved in the maturation of melanocytes to produce melanin and undergo appropriate differentiation [39]. Vitamin D is also thought to play a role in immunomodulation, although the mechanism is not well understood. Studies have indicated the use of vitamin D in the treatment of autoimmune diseases such as systemic lupus erythematosus, diabetes mellitus, rheumatoid arthritis, and multiple sclerosis, although this topic is highly controversial [40].

In particular, Silverberg *et al.* studied the relationship between serum 25-hydroxyvitamin D levels and the presence of autoimmune diseases. It was found that very low 25-hydroxyvitamin D level (<15 ng/mL) in patients with vitiligo was associated with comorbid autoimmune disease, such as thyroid disease, Sjögren syndrome, rheumatoid arthritis, alopecia areata, and inflammatory bowel disease [41].

Looking at serum levels of vitamin D in vitiligo from a different perspective, Sehwat *et al.* analyzed the levels of 25-hydroxyvitamin D in Indian patients with vitiligo throughout a 12-week phototherapy treatment consisting of three NB-UVB sessions per week. Interestingly, all of the patients had sub-normal levels of serum 25-hydroxyvitamin D at the start of the study, but throughout the course of NB-UVB treatment, serum 25-hydroxyvitamin D levels increased. Additionally, this group reported a significant improvement in VASI scores as repigmentation occurred throughout the treatment. Although the increasing trend of serum vitamin D levels was insignificant, this study provided interesting insight into the potential role of vitamin D in the repigmentation of vitiligo lesions, perhaps through the regulation of photo-induced melanogenesis [42].

Additional studies by Finamor *et al.* supported this theory, as they assessed the effect of long-term administration of 25-hydroxyvitamin D in the treatment of patients with vitiligo and psoriasis. Sixteen vitiligo patients were treated with 35,000 IU of 25-hydroxyvitamin D daily for six months, and as expected, measured serum levels of vitamin D increased significantly throughout the study. Additionally, eleven out of the sixteen patients with vitiligo experienced 25-75% repigmentation during this time period [43]. Increases in serum vitamin D levels were associated with corresponding repigmentation. This study raises the possibility of vitamin D supplementation as a treatment option for patients with vitiligo [43]. However, further studies are needed for a more complete understanding of the mechanism and clinical utility of vitamin D supplementation, as this topic is controversial and in need of further evidence. Of note, vitamin D is a fat-soluble vitamin, which can reach toxic levels if ingested in excess. Toxicity is defined as vitamin D levels higher than 150 ng/mL, or the presence of associated symptoms such as hypercalcemia, nausea, constipation, or weakness. Although daily recommendations are controversial, toxicity is unlikely in an adult when taking doses less than 10,000 IU daily. Additionally, a safe daily limit, as recommended by the Institute of Medicine, is 4,000 IU daily for individuals older than 8 years of age [44, 45]. Table 4 and 5 lists the recommended daily allowance for vitamin D as well as foods rich in vitamin D.

**Table 4. Selected foods rich in Vitamin D [15].**

Foods	Measure	Vitamin D (D2 + D3) (ug) per measure	% RDA (600 IU or 15 ug)	% UL (40,000 ug/day)
Mushrooms – brown, Italian or crimini (raw)	1.0 cup	27.8	185	0.70
Salmon, canned	3.0 oz	18.3	122	0.46
Smoked whitefish	1.0 cup	17.4	116	0.43
Mushrooms – portabella, grilled	1.0 cup sliced	15.9	106	0.40
Salmon, cooked	3.0 oz	14.1	94	0.35
Swordfish, cooked	3.0 oz	14.1	94	0.35
Rainbow trout, cooked	1.0 fillet	13.5	90	0.34
Tuna, canned	1.0 cup	9.8	65	0.25
Milk (whole), added vitamin D	0.25 cup	3.4	23	0.23
Hardboiled egg	1.0 cup	3.0	20	0.07

## E. Alternative Medicine

A variety of alternative treatment practices have been used as therapeutic remedies for vitiligo, although there is a paucity of clinical studies in the literature. Many of these treatments utilize herbs and extracts with photosensitizing properties in conjunction with natural sunlight to induce repigmentation. These practices include Ayurvedic, Unani, and Traditional Chinese medicine (TCM) techniques [26].

Ayurvedic medicine was developed in India thousands of years ago and is still practiced today. This form of medicine takes a holistic approach toward the patient, incorporating spirit, body, mind, and emotions and often involves dietary modifications. Dietotherapy for vitiligo includes Saman Chikitsa, which consists of two parts, Kastha Aushadhi and Saman Chikitsa. Kastha Aushadhi uses herbal supplements as photosensitizing and blood-purifying treatments, whereas Rasa Shastra is a method of formulating combinations of herbs and minerals for immunosuppression. The list of herbs used in both is extensive, and the dosing and regimens are often Ayurvedic practitioner and pharmacy dependent, making it difficult to provide exact regimens. An additional form of Ayurvedic treatment for vitiligo is Sodhan Chikitsa, a method of purification of the body through the use of vomiting, purgation, enemas, and bloodletting. This practice involves the use of laxatives, bran, flaxseed, fruits, and many other dietary agents [26].

Unani medicine is derived from influences of Greek, Islamic, and Arabic cultures, and is practiced today in many parts of the Middle East, South Africa and regions of Asia. According to this practice, the human body is composed of the following four components: air, water, fire, and earth. An imbalance of these elements is thought to be the causative factor in illness and disease. Treatment regimens were developed surrounding this ideology. In addition to Iiaj Nafansi (psychotherapy), Unani medicine recommends the use of Iiaj Bil Ghiza (dietotherapy) for the treatment of vitiligo. Helpful foods according to this practice are listed as follows; warm, easily digestible foods, goat and bird meat, and digestive aids with meals. Additionally, the avoidance of fresh fish, fruits, vegetables, and foods high in fat is recommended, as these foods are theorized to cause an imbalance in the elements of the body [26].

Traditional Chinese Medicine (TCM), which was developed and practiced in China, views the human body as a combination of two opposing but complementary forces, the Ying and Yang. An imbalance in the Ying and Yang is thought to produce illness and disease. This practice uses a holistic approach in patient management, by combining physical, oral, and acupuncture practices in the management or prevention of disease. In particular, TCM dietary treatments for vitiligo include the use of herbal supplements, such as Golden Serpent fern extract in combination with NBUVB, *Ginkgo biloba*, and Xiaobai Mixture, a blend of walnut, flowers, black sesame, black beans, duckweed, Sweetgum fruit, and plums [26]. Chen et al. assessed the effectiveness of a combination of oral TCM with NBUVB therapy compared to NBUVB alone in a systematic review with meta-analysis of randomized controlled trials. This study determined that in regards to repigmentation, CHM combined with phototherapy was superior to phototherapy alone in the treatment of vitiligo ( $p < 0.00001$ ) [46].

Supplementation regimens in these practices are difficult to quantify and not commonly used in the United States. Future studies are necessary and may further elucidate the role of alternative medicine in the management of vitiligo.

## CONCLUSION

Vitiligo is a complex disease with a multitude of components contributing to its pathogenesis. Alterations in the diet may target many of these components, and recent evidence suggests that dietary modifications and supplementation can be beneficial in the treatment of vitiligo, especially as adjuvant therapies to phototherapy or topical regimens. Although initial findings with these supplements are promising, further studies in multiple populations are needed to explore the therapeutic value of these interventions and further develop these options to optimize the management of this psychologically devastating disease.

**Table 5. Compiled list of Recommended Dietary Allowances (RDA) and Upper Intake Level (UL) of discussed vitamins and minerals [47].**

Substance	RDA: 19-30 years, 30-50 years, and 50-70 years	UL: 19-30 years, 30-50 years, and 50-70 years
Copper	900 ug/day	10,000 ug/day
Vitamin C	Males: 90 mg/day, Females: 75 mg/day	2,000 mg/day
Vitamin D	600 IU/day	4,000 IU/day
Vitamin E	15 mg/day	1,000 mg/day
Zinc	Males: 11 mg/day, Females: 8 mg/day	40 mg/day

## CONFLICT OF INTEREST

Dr. Hamzavi is an investigator for Estee-Lauder, Ferndale, Johnson and Johnson, and Allergan, and has received equipment from Johnson and Johnson. Dr. Mohammad is a subinvestigator for Estee-Lauder, Ferndale, and Allergan. Ms. Smith has no conflicts of interest to report.

## ACKNOWLEDGEMENTS

Declared none.

## REFERENCES

- [1] Ezzedine K, Eleftheriadou V, Whitton M, van Geel N. Vitiligo. *Lancet* 2015; 386(9988): 74-84. [[http://dx.doi.org/10.1016/S0140-6736\(14\)60763-7](http://dx.doi.org/10.1016/S0140-6736(14)60763-7)] [PMID: 25596811]
- [2] Alikhan A, Felsten LM, Daly M, Petronic-Rosic V. Vitiligo: A comprehensive overview Part I. Introduction, epidemiology, quality of life, diagnosis, differential diagnosis, associations, histopathology, etiology, and work-up. *J Am Acad Dermatol* 2011; 65(3): 473-91. [<http://dx.doi.org/10.1016/j.jaad.2010.11.061>] [PMID: 21839315]
- [3] Gauthier Y, Cario Andre M, Taïeb A. A critical appraisal of vitiligo etiologic theories. Is melanocyte loss a melanocytorrhagy? *Pigment Cell Res* 2003; 16(4): 322-32. [<http://dx.doi.org/10.1034/j.1600-0749.2003.00070.x>] [PMID: 12859615]
- [4] Taïeb A, Picardo M. Clinical practice. Vitiligo. *N Engl J Med* 2009; 360(2): 160-9. [PMID: 19129529]
- [5] Gill L, Zarbo A, Isedeh P, Jacobsen G, Lim HW, Hamzavi I. Comorbid autoimmune diseases in patients with vitiligo: A cross-sectional study. *J Am Acad Dermatol* 2016; 74(2): 295-302. [<http://dx.doi.org/10.1016/j.jaad.2015.08.063>] [PMID: 26518171]
- [6] Güntaş G, Engin B, Ekmekçi OB, *et al.* Evaluation of advanced oxidation protein products, prooxidant-antioxidant balance, and total antioxidant capacity in untreated vitiligo patients. *Ann Dermatol* 2015; 27(2): 178-83. [<http://dx.doi.org/10.5021/ad.2015.27.2.178>] [PMID: 25834357]
- [7] Sisti A, Sisti G, Oranges CM. Effectiveness and safety of topical tacrolimus monotherapy for repigmentation in vitiligo: A comprehensive literature review. *An Bras Dermatol* 2016; 91(2): 187-95. [<http://dx.doi.org/10.1590/abd1806-4841.20164012>] [PMID: 27192518]
- [8] Felsten LM, Alikhan A, Petronic-Rosic V. Vitiligo: a comprehensive overview Part II: treatment options and approach to treatment. *J Am Acad Dermatol* 2011; 65(3): 493-514. [<http://dx.doi.org/10.1016/j.jaad.2010.10.043>] [PMID: 21839316]
- [9] Xie H, Zhou F, Liu L, *et al.* Vitiligo: How do oxidative stress-induced autoantigens trigger autoimmunity? *J Dermatol Sci* 2016; 81(1): 3-9. [<http://dx.doi.org/10.1016/j.jdermsci.2015.09.003>] [PMID: 26387449]
- [10] Yildirim M, Baysal V, Inaloz HS, Can M. The role of oxidants and antioxidants in generalized vitiligo at tissue level. *J Eur Acad Dermatol Venereol* 2004; 18(6): 683-6. [<http://dx.doi.org/10.1111/j.1468-3083.2004.01080.x>] [PMID: 15482295]
- [11] Khan R, Satyam A, Gupta S, Sharma VK, Sharma A. Circulatory levels of antioxidants and lipid peroxidation in Indian patients with generalized and localized vitiligo. *Arch Dermatol Res* 2009; 301(10): 731-7. [<http://dx.doi.org/10.1007/s00403-009-0964-4>] [PMID: 19488773]
- [12] Colucci R, Dragoni F, Conti R, Pisaneschi L, Lazzeri L, Moretti S. Evaluation of an oral supplement containing *Phyllanthus emblica* fruit extracts, vitamin E, and carotenoids in vitiligo treatment. *Dermatol Ther (Heidelb)* 2015; 28(1): 17-21. [<http://dx.doi.org/10.1111/dth.12172>] [PMID: 25285994]
- [13] Dell'Anna ML, Mastrofrancesco A, Sala R, *et al.* Antioxidants and narrow band-UVB in the treatment of vitiligo: a double-blind placebo controlled trial. *Clin Exp Dermatol* 2007; 32(6): 631-6. [<http://dx.doi.org/10.1111/j.1365-2230.2007.02514.x>] [PMID: 17953631]
- [14] Elgoweini M, Nour El Din N. Response of vitiligo to narrowband ultraviolet B and oral antioxidants. *J Clin Pharmacol* 2009; 49(7): 852-5. [<http://dx.doi.org/10.1177/0091270009335769>] [PMID: 19553407]
- [15] USDA Food Composition Databases Available from: <https://ndb.nal.usda.gov/ndb/nutrients/index> 2016 [09/15/2016];
- [16] Choudhry SZ, Bhatia N, Ceilley R, *et al.* Role of oral *Polypodium leucotomos* extract in dermatologic diseases: A review of the literature. *J Drugs Dermatol* 2014; 13(2): 148-53. [PMID: 24509964]
- [17] Berman B, Ellis C, Elmets C. *Polypodium Leucotomos* An Overview of Basic Investigative Findings. *J Drugs Dermatol* 2016; 15(2): 224-8. [PMID: 26885792]
- [18] Nestor M, Bucay V, Callender V, Cohen JL, Sadick N, Waldorf H. *Polypodium leucotomos* as an Adjunct Treatment of Pigmentary Disorders. *J Clin Aesthet Dermatol* 2014; 7(3): 13-7. [PMID: 24688621]
- [19] Middelkamp-Hup MA, Bos JD, Rius-Diaz F, Gonzalez S, Westerhof W. Treatment of vitiligo vulgaris with narrow-band UVB and oral *Polypodium leucotomos* extract: a randomized double-blind placebo-controlled study. *J Eur Acad Dermatol Venereol* 2007; 21(7): 942-50. [<http://dx.doi.org/10.1111/j.1468-3083.2006.02132.x>] [PMID: 17659004]
- [20] Pacifico AI, Paro Vidolin A, Leone G. Combined treatment of narrowband ultraviolet B light (NBUVB) phototherapy and oral *polypodium leucotomos* extract versus NB UVB phototherapy alone in the treatment of patients with vitiligo. *J Am Acad Dermatol* 2009; 60.



- [21] Reyes E, Jaén P, de las Heras E, *et al.* Systemic immunomodulatory effects of Polypodium leucotomos as an adjuvant to PUVA therapy in generalized vitiligo: A pilot study. *J Dermatol Sci* 2006; 41(3): 213-6. [<http://dx.doi.org/10.1016/j.jdermsci.2005.12.006>] [PMID: 16423508]
- [22] Nestor MS, Berman B, Swenson N. Safety and efficacy of oral polypodium leucotomos extract in healthy adult subjects. *J Clin Aesthet Dermatol* 2015; 8(2): 19-23. [PMID: 25741399]
- [23] Parsad D, Pandhi R, Juneja A. Effectiveness of oral Ginkgo biloba in treating limited, slowly spreading vitiligo. *Clin Exp Dermatol* 2003; 28(3): 285-7. [<http://dx.doi.org/10.1046/j.1365-2230.2003.01207.x>] [PMID: 12780716]
- [24] Szczurko O, Shear N, Taddio A, Boon H. Ginkgo biloba for the treatment of vitiligo vulgaris: an open label pilot clinical trial. *BMC Complement Altern Med* 2011; 11: 21. [<http://dx.doi.org/10.1186/1472-6882-11-21>] [PMID: 21406109]
- [25] Ernst E. The risk-benefit profile of commonly used herbal therapies: Ginkgo, St. Johns Wort, Ginseng, Echinacea, Saw Palmetto, and Kava. *Ann Intern Med* 2002; 136(1): 42-53. [<http://dx.doi.org/10.7326/0003-4819-136-1-200201010-00010>] [PMID: 11777363]
- [26] Hamzavi IH. BH, Isedeh PN *Handbook of Vitiligo*. London: JP Medical Ltd. 2016.
- [27] Wu X, Beecher GR, Holden JM, Haytowitz DB, Gebhardt SE, Prior RL. Lipophilic and hydrophilic antioxidant capacities of common foods in the United States. *J Agric Food Chem* 2004; 52(12): 4026-37. [<http://dx.doi.org/10.1021/jf049696w>] [PMID: 15186133]
- [28] Seyhan M, Erdem T, Ertekin V, Selimoğlu MA. The mucocutaneous manifestations associated with celiac disease in childhood and adolescence. *Pediatr Dermatol* 2007; 24(1): 28-33. [<http://dx.doi.org/10.1111/j.1525-1470.2007.00328.x>] [PMID: 17300645]
- [29] Seyhan M, Kandi B, Akbulut H, Selimoğlu MA, Karıncaoğlu M. Is celiac disease common in patients with vitiligo? *Turk J Gastroenterol* 2011; 22(1): 105-6. [<http://dx.doi.org/10.4318/tjg.2011.0169>] [PMID: 21480124]
- [30] Shahmoradi Z, Najafian J, Naeini FF, Fahimpour F. Vitiligo and autoantibodies of celiac disease. *Int J Prev Med* 2013; 4(2): 200-3. [PMID: 23543680]
- [31] Rodríguez-García C, González-Hernández S, Pérez-Robayna N, Guimerá F, Fagundo E, Sánchez R. Repigmentation of vitiligo lesions in a child with celiac disease after a gluten-free diet. *Pediatr Dermatol* 2011; 28(2): 209-10. [<http://dx.doi.org/10.1111/j.1525-1470.2011.01388.x>] [PMID: 21504457]
- [32] Khandalavala BN, Nirmalraj MC. Rapid partial repigmentation of vitiligo in a young female adult with a gluten-free diet. *Case Rep Dermatol* 2014; 6(3): 283-7. [<http://dx.doi.org/10.1159/000370303>] [PMID: 25685131]
- [33] Shameer P, Prasad PV, Kaviarasan PK. Serum zinc level in vitiligo: a case control study. *Indian J Dermatol Venereol Leprol* 2005; 71(3): 206-7. [<http://dx.doi.org/10.4103/0378-6323.16243>] [PMID: 16394417]
- [34] Zeng Q, Yin J, Fan F, *et al.* Decreased copper and zinc in sera of Chinese vitiligo patients: a meta-analysis. *J Dermatol* 2014; 41(3): 245-51. [<http://dx.doi.org/10.1111/1346-8138.12392>] [PMID: 24517587]
- [35] Mohammed GF, Gomaa AH, Al-Dhubaibi MS. Highlights in pathogenesis of vitiligo. *World J Clin Cases* 2015; 3(3): 221-30. [<http://dx.doi.org/10.12998/wjcc.v3.i3.221>] [PMID: 25789295]
- [36] Hassan MI, Waheed A, Yadav S, Singh TP, Ahmad F. Zinc alpha 2-glycoprotein: a multidisciplinary protein. *Mol Cancer Res* 2008; 6(6): 892-906. [<http://dx.doi.org/10.1158/1541-7786.MCR-07-2195>] [PMID: 18567794]
- [37] Arora PN, Dhillon KS, Rajan SR, Sayal SK, Das AL. Serum Zinc Levels in Cutaneous Disorders. *Med J Armed Forces India* 2002; 58(4): 304-6. [[http://dx.doi.org/10.1016/S0377-1237\(02\)80083-1](http://dx.doi.org/10.1016/S0377-1237(02)80083-1)] [PMID: 27407419]
- [38] Yaghoobi R, Omidian M, Bagherani N. Original article title: Comparison of therapeutic efficacy of topical corticosteroid and oral zinc sulfate-topical corticosteroid combination in the treatment of vitiligo patients: a clinical trial. *BMC Dermatol* 2011; 11: 7. [<http://dx.doi.org/10.1186/1471-5945-11-7>] [PMID: 21453467]
- [39] Parsad D, Kanwar AJ. Topical vitamin D analogues in the treatment of vitiligo. *Pigment Cell Melanoma Res* 2009; 22(4): 487-8. [<http://dx.doi.org/10.1111/j.1755-148X.2009.00579.x>] [PMID: 19422605]
- [40] AlGhamdi K, Kumar A, Moussa N. The role of vitamin D in melanogenesis with an emphasis on vitiligo. *Indian J Dermatol Venereol Leprol* 2013; 79(6): 750-8. [<http://dx.doi.org/10.4103/0378-6323.120720>] [PMID: 24177606]
- [41] Silverberg JI, Silverberg AI, Malka E, Silverberg NB. A pilot study assessing the role of 25 hydroxy vitamin D levels in patients with vitiligo vulgaris. *J Am Acad Dermatol* 2010; 62(6): 937-41. [<http://dx.doi.org/10.1016/j.jaad.2009.11.024>] [PMID: 20466170]

- [42] Sehrawat M, Arora TC, Chauhan A, Kar HK, Poonia A, Jairath V. Correlation of Vitamin D Levels with Pigmentation in Vitiligo Patients Treated with NBUVB Therapy. *ISRN Dermatol* 2014; 2014: 493213. [<http://dx.doi.org/10.1155/2014/493213>] [PMID: 25006488]
- [43] Finamor DC, Sinigaglia-Coimbra R, Neves LC, *et al.* A pilot study assessing the effect of prolonged administration of high daily doses of vitamin D on the clinical course of vitiligo and psoriasis. *Dermatoendocrinol* 2013; 5(1): 222-34. [<http://dx.doi.org/10.4161/derm.24808>] [PMID: 24494059]
- [44] Reddy KK, Gilchrist BA. Iatrogenic effects of photoprotection recommendations on skin cancer development, vitamin D levels, and general health. *Clin Dermatol* 2011; 29(6): 644-51. [<http://dx.doi.org/10.1016/j.clindermatol.2011.08.027>] [PMID: 22014986]
- [45] Holick MF. Vitamin D deficiency. *N Engl J Med* 2007; 357(3): 266-81. [<http://dx.doi.org/10.1056/NEJMra070553>] [PMID: 17634462]
- [46] Chen YJ, Chen YY, Wu CY, Chi CC. Oral Chinese herbal medicine in combination with phototherapy for vitiligo: A systematic review and meta-analysis of randomized controlled trials. *Complement Ther Med* 2016; 26: 21-7. [<http://dx.doi.org/10.1016/j.ctim.2016.02.009>] [PMID: 27261977]
- [47] Recommendations N. Nutrient Recommendations: Dietary Reference Intakes (DRI): U.S. Department of Health and Human Services; [Available from: [https://ods.od.nih.gov/Health\\_Information/Dietary\\_Reference\\_Intakes.aspx](https://ods.od.nih.gov/Health_Information/Dietary_Reference_Intakes.aspx) 2016.

© 2017 Smith *et al.*

This is an open access article distributed under the terms of the Creative Commons Attribution 4.0 International Public License (CC-BY 4.0), a copy of which is available at: (<https://creativecommons.org/licenses/by/4.0/legalcode>). This license permits unrestricted use, distribution, and reproduction in any medium, provided the original author and source are credited.