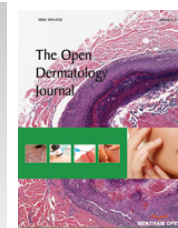




The Open Dermatology Journal

Content list available at: www.benthamopen.com/TODJ/

DOI: 10.2174/1874372201711010098



CLINICAL TRIAL STUDY

Prospective Pilot Evaluation of the Efficacy and Safety of Topical Ingenol Mebutate Gel for Localized Patch/Plaque Stage Mycosis Fungoides

Eve Lebas¹, Charlotte Castronovo¹, Jorge E. Arrese², Florence Libon¹, Nazli Tassoudji¹, Laurence Seidel³ and Arjen F. Nikkels^{1,*}

¹Dermatology (Dermato-oncology unit), University Hospital Centre, CHU du Sart Tilman, Liège, Belgium

²Dermatopathology, University Hospital Centre, CHU du Sart Tilman, Liège, Belgium

³Biostatistics University Hospital Centre, CHU du Sart Tilman, Liège, Belgium

Received: September 29, 2017

Revised: December 05, 2017

Accepted: December 14, 2017

Abstract:

Background:

Mycosis Fungoides (MF) is the most frequent type of the primary cutaneous NK/T-cell lymphomas. Ingenol mebutate (IM) displays *in vitro* pro-apoptotic properties on neoplastic lymphocytes.

Objectives:

To evaluate the efficacy and safety of IM gel as topical treatment for MF.

Materials and Methods:

Ten male patients with longstanding classic type MF (n=9) and follicular MF (FMF; n=1), T2bN0M0B0, stage Ib, resistant to systemic methotrexate or acitretin therapies for at least 3 months, were included in this pilot study. In these patients, 11 target patch/plaque stage lesions with an area ≤ 25 cm² were selected for IM therapy (0,05%, 2 weekly applications). The primary endpoint was the improvement of the CAILS scores. Biopsies were performed before and after treatment from 10 target lesions. Relapse rates were evaluated at 6 months.

Results:

The mean CAILS score of treated target lesions was reduced by 58.2%. The mean erythema, scaling and plaque elevation scores were improved by 73.6%, 93.9% and 97.9% (p<0.0001), respectively, while the lesion size remained unchanged (p=0.34). A complete or partial clearance of histological and immunohistochemical features was observed in 6/10 (60%) and 4/10 (40%) of the MF or FMF target lesions, respectively. Monoclonal TCR rearrangement was evidenced in 100% (7/7) of the patients and in 3/7 (43%) after treatment. The relapse rate at 6 months was 18%. All the patients experienced burning sensations, oozing and crusting.

Conclusion:

IM gel warrants further investigation and development as a potential topical treatment for localized patch/plaque stage MF and FMF.

Keywords: Ingenol Mebutate, Mycosis Fungoides, PCNKTCL, Alternative Topical Treatment Option.

* Address correspondence to this author at the Department of Dermatology, CHU of Sart Tilman, University of Liège, B-4000, Liège, Belgium; Tel: +32-43667232; Fax: +32-43667234; E-mail: af.nikkels@chu.ulg.ac.be

1. INTRODUCTION

Ingenol Mebutate (IM) is a macrocyclic diterpene ester and originates from the plant *Euphorbia peplus* (PEP005, 0,015%, 0,05%, Picato^o gel, Leo Pharma) [1, 2]. For decades the sap from *E. peplus* has been used as traditional medicine for various types of skin cancer [1, 2]. Both the EMA and the FDA recognize IM gel as a field-directed treatment for Actinic Keratosis (AK) [1, 2]. IM also revealed to be an efficacious topical treatment for other cutaneous (Fig. 3) epithelial cancers, including superficial basal cell carcinoma [3 - 5], Bowen's disease [6, 7] and murine cutaneous squamous cell carcinoma [8]. IM has also demonstrated activity against melanoma cell lines *in vitro* [9, 10] and, *in vivo*, for Dubreuilh's melanoma of the face [11].

IM and other ingenol derivatives activate multiple signaling pathways in cancer cells, including the intracellular pro-apoptotic Protein Kinase C (PKC) δ , α and ϵ , NF- κ B1, ERK, JNK and Akt pathways [10, 12]. The activation of these PKC's leads to a rapid cancer cell apoptosis and a neutrophil-mediated immunostimulation of antibody-dependent cellular cytotoxic response [13]. The IM-induced pro-inflammatory and pro-apoptotic storm could potentially be of therapeutic benefit for atypical lymphocytes. Ingenol 3-angelate has previously been demonstrated to be effective against murine B-lymphoma cells [12]. IM induced apoptosis in acute myeloid leukemia cells by activating the PKC isoform PKC δ [14].

The classic type of Mycosis Fungoides (MF) is the most frequent form of the primary Cutaneous T/NK Cell Lymphomas (pCTNKCL). MF follows typically an indolent cutaneous disease course and is an ideal candidate for skin-directed therapies. Its folliculotropic variant (FMF) is a more rare and late-stage FMF may present a more aggressive disease course [15 - 18].

In the view of the action mechanisms of IM, we were interested to evaluate whether IM gel 0,05% had a potential effect on patch/plaque stage lesions in MF and FMF patients that were previously resistant to systemic methotrexate or acitretin.

This prospective pilot study assessed the improvement of the CAISL (Composite Assessment of Index Lesion Severity) score [19] and the histological cure rate 2 months after using IM gel on 11 target lesions in 10 patients with histologically confirmed, longstanding patch/plaque stage MF and FMF.

2. MATERIALS AND METHODS:

2.1. Institutional Ethics

This prospective pilot study was performed in accordance with the ethical standard of the University Hospital Committee on institutional human experimentation and with the Helsinki Declaration of 1975, and amended in 2013. The aims of the study and all the procedures were explained to all the patients and all signed an informed consent.

2.2. Patient Selection

At baseline, the patients had to present patch/plaque stage lesions that were not responding to at least 3 months of oral methotrexate or acitretin treatments. Patients were selected between Feb and May 2017. The individual patient demographics, including age, gender, type of underlying MF, TNMB staging and disease stage, mSWAT (modified Severity-Weighted Assessment Tool) score of the underlying MF at baseline, as well as the site of the selected target lesion are summarized in Table 1. All the patients had longstanding patch/plaque type classic type MF (n=9) or FMF (n=1). The diagnosis of classic type MF or FMF was made histologically at least 4 years before inclusion in the study and sustained by an immunohistochemical CD3+, CD4+, CD45R0+ and CD8- expression profile of the MF infiltrate and by the presence of a monoclonal T-Cell Receptor (TCR) rearrangement (10/10 cases).

Table 1. Patient Demographics.

| Patient | Gender, Age | Type, TNMB, Stage, mSWAT | Target Lesion Site(s) | Duration of MF (years) |
|---------|-------------|------------------------------------|-----------------------|------------------------|
| 1 | M, 64 years | FMF, T2bN0M0B0, Ib, 30 | Perineal | > 7 |
| 2 | M, 52 years | MF, classic type T2bN0M0B0, Ib, 82 | Left arm | > 5 |
| 3 | M, 70 years | MF, classic type T2bN0M0B0, Ib, 56 | Left arm | > 8 |
| 4 | M, 62 years | MF, classic type T2bN0M0B0, Ib, 84 | Right arm | > 5 |
| 5 | M, 73 years | MF, classic type T2bN0M0B0, Ib, 74 | Chest | > 4 |
| 6 | M, 76 years | MF, classic type T2bN0M0B0, Ib, 88 | Knee | > 5 |

(Table 1) *contd....*

| Patient | Gender, Age | Type, TNMB, Stage, mSWAT | Target Lesion Site(s) | Duration of MF (years) |
|---------|-----------------------|------------------------------------|-----------------------|-----------------------------------|
| 7 | M, 79 years | MF, classic type T2bN0M0B0, Ib, 48 | Knee | > 8 |
| 8 | M, 80 years | MF, classic type T2bN0M0B0, Ib, 42 | Axillar | > 4 |
| 9 | M, 65 years | MF, classic type T2bN0M0B0, Ib, 78 | Buttock | > 5 |
| 10 | M, 72 years | MF, classic type T2bN0M0B0, Ib, 44 | Inguinal Abdominal | > 6 |
| | Mean age: 69 years | Mean mSWAT score: 59.6 | | Mean duration of MF: 5.7 years |

2.3. Target Site Selection

Per patient, one or two target patch/plaque type lesion(s) of 3 to 7 cm in diameter were selected. Target lesions had to be present without any clinical changes since at least 3 months. Target lesions exceeding 25 cm² were excluded, as manufacturer instructions say to treat an area of not more than 25 cm².

2.4. Control Site Selection

One or more control lesions in the immediate vicinity of the target lesion were selected. The size of the control lesions was up to 25 cm². The control lesions had to present a clinical highly similar aspect as the target lesion.

2.5. Photographic Recording

Photographic recordings were made of every target lesion and control lesion(s) under standard conditions at baseline (T0) and at 2 months after therapy (T2).

2.6. Treatment Application

One tube of IM gel (0,05%, 235 µg of IM in 0,47 g of gel, Leo Pharma^o) was applied to the target lesion at day 1 and day 7. The 0,05% formulation was selected, as none of the target lesions was located on the face. Patients were informed concerning potential adverse effects and how to manage them. The one-week interval between IM applications was selected to avoid too severe cutaneous adverse reactions as sometimes observed in AK patients with the 2 consecutive days IM application regimen, and furthermore, to be able to judge the severity of the cutaneous reactions after one single application and to reduce the severity the IM-treatment-related adverse effects. The control lesions did not receive any topical treatment. No other topical treatments were allowed for the target and control lesions during the entire study. The previous oral treatments were interrupted three months before inclusion.

2.7. Histology, Immunohistology and TCR

A 4-mm cutaneous punch biopsy of the target lesion was obtained under local anesthesia, fixed in neutralized formalin 4% and embedded in paraffin before and 2 months after treatment. Histopathological examination for MF criteria was performed. The histologic scoring system was the following: no change compared to baseline, a partial improvement (at least 75%) of the MF infiltrate or a total resolution (with or without persistence of post-inflammatory lymphohistiocytic infiltrate and/or post-inflammatory hyperpigmentation). Immunohistochemistry searched for CD3, CD4, CD45R0 and CD8 expressions. Immunohistological scoring was as follows: no change compared to baseline, partial resolution (at least 75% improvement) and total healing in terms of CD3, CD4, CD45R0 and CD8 expression. TCR monoclonal rearrangements were evaluated as present or absent at baseline and 2 months after treatment from 7 target lesions. No histology was performed for the control lesions.

2.8. CAILS Score

The primary endpoint in this pilot setting was the mean CAILS (Composite Assessment of Index Lesion Severity) score improvement, expressed in percentage (T0-T2), evaluating the erythema, scaling, plaque elevation and hyper/hypopigmentation scores (all: ranging from 0 (none) to 8 (very severe)) as well as the lesion size (1: up to 4 cm² up to maximum 4: 16-25 cm²), as used for individual lesion evaluation, before (T0) and 2 months (T2) after treatment of the target and control lesions [19].

2.9. Local Adverse Effects

Cutaneous local adverse effects assessment was performed 5 days after the first and second IM application. The scoring of burning sensations, oozing, and crusting used the following scale: 0: none, 1: mild, 2: moderate and 3:

severe. No evaluation of eventual systemic adverse effects was included in this pilot study as no such effects were previously reported in AK studies [1 - 5].

2.10. Recurrence Rate

The clinical relapse rate of the target lesion was assessed 6 months after the initiation of the IM treatment. Relapse was defined as the re-appearance of the patch/plaque infiltration and/or erythema and/or scaling.

2.11. Statistical Analysis

A comparison of the mean relative differences (T0 and T2) between target and control was made using the Student test for the individual CAILS parameters, erythema, scaling, plaque elevation, hyper/hypopigmentation and lesion size (L. Seidel).

3. RESULTS

3.1. Histology, Immunohistology and TCR

Punch biopsies were obtained from 10 target lesions before IM treatment (T0) and at 2 months after treatment (T2). Histopathological examination revealed a complete or partial absence of histological signs and immunohistochemical features of MF or FMF in 6/11 (55%) and 4/11 (36%) target lesions, respectively (Figs. 1 and 2). Monoclonal TCR rearrangement of the target lesions before treatment was positive in 7/7 (100%) cases and in 3/7 (43%) at 2 months post-treatment.

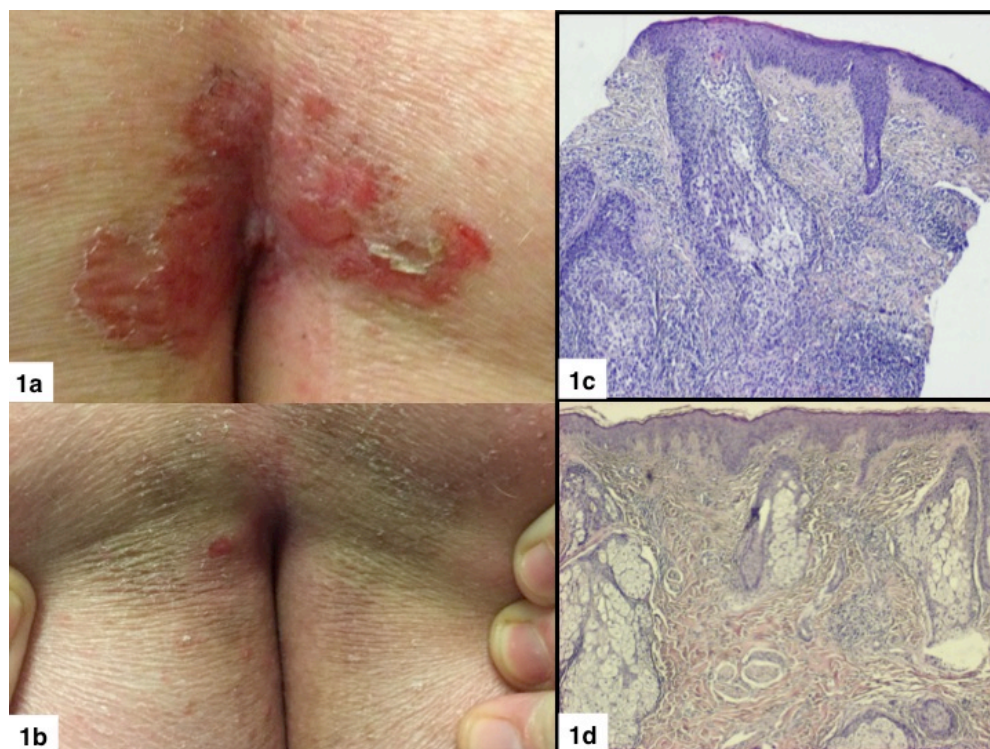


Fig. (1). **a.** Target lesion of a folliculotropic pCTNKCL on the buttocks. **b.** Complete clinical cure after 2 months. **c.** Histology illustrating folliculotropic pCTNKCL before treatment (H/E histochemical stain, 40x). **d.** Histological clearing of atypical lymphocytes two months after IM treatment (H/E histochemical stain, 10x).

3.2. CAILS Scores

The study results are listed in Tables 2 and 3. The mean overall CAILS score (T0-T2) was reduced by 58.2%. The erythema, scaling and plaque elevation mean scores (T0-T2) were improved by 73.6%, 93.9% and 97.7% respectively, all statistically significant ($p < 0.0001$). No hyper or hypopigmentation was observed at baseline. Mild to moderate hyperpigmentation appeared in 8/11 (73%) of the target lesions. No reduction in lesion size was observed in any of the

target and control lesions (Figs. 1-4).

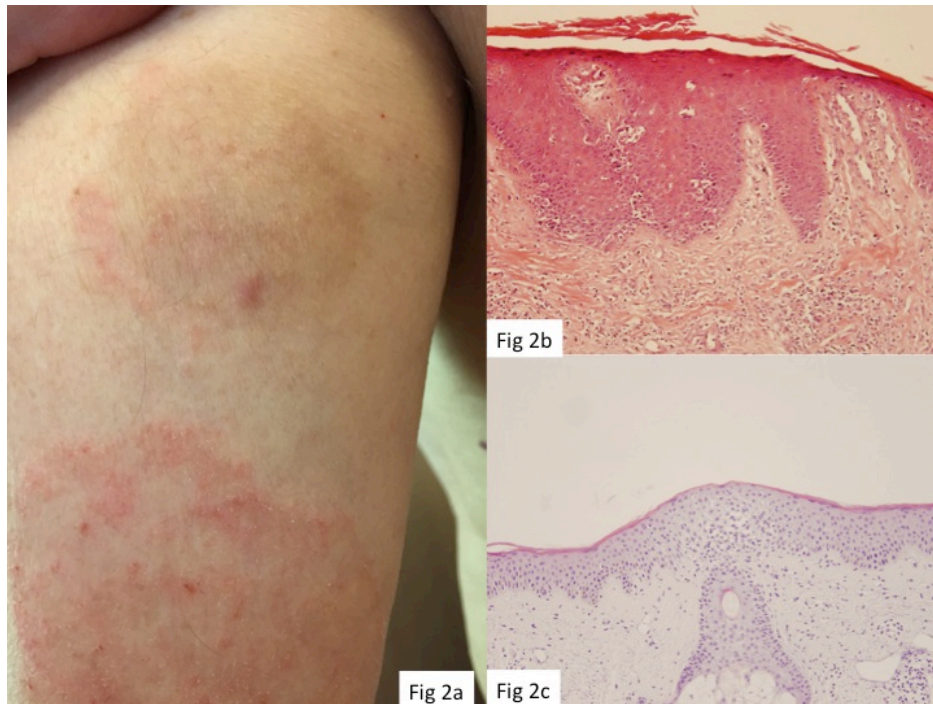


Fig. (2). **a.** Hyperpigmented postinflammatory target MF lesion (yellow arrow) and erythematous-squamous control MF lesion (red arrow) 2 months after treatment. **2b.** Histology illustrating patch/plaque stage MF before and **2c.** Histological clearing 2 months after treatment (H/E histochemical stain, x10).

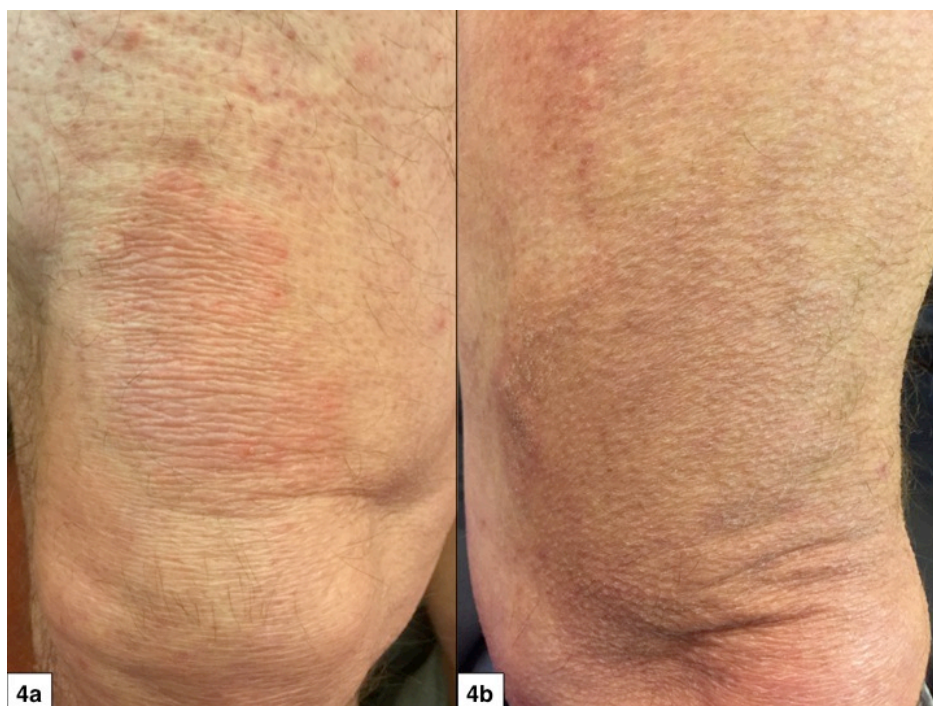


Fig. (3). **a.** Patch/plaque stage MF of the knee, **3b,** 2 months after treatment. Note slight persistent hyperpigmentation.

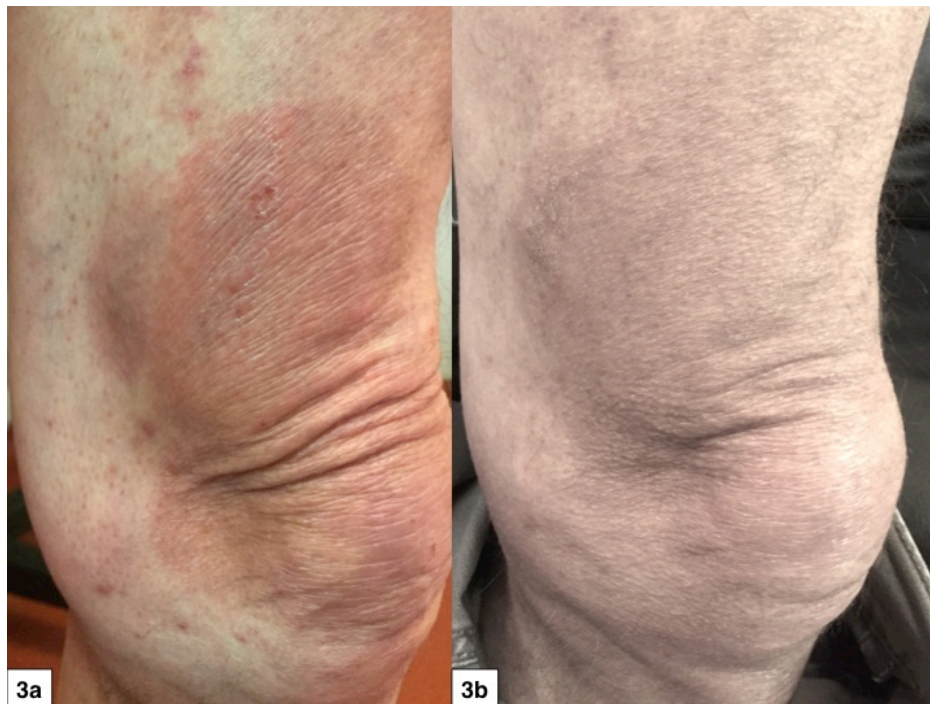


Fig. (4). a. Patch/plaque stage MF of the knee, 4b. 2 months after treatment. Note slight persistent hyperpigmentation.

Table 2. Mean absolute differences between T0 and T2 and significance of the difference.

| Variable | N | Mean | SD | SE | Min | Q1 | Median | Q3 | Max | Student p-value |
|--------------|----|--------|-------|------|------|------|--------|------|------|-----------------|
| ErythdT0T2 | 11 | 3.818 | 1.401 | 0.42 | 2.0 | 3.0 | 4.00 | 5.0 | 6.0 | <.0001 |
| ScalingdT0T2 | 11 | 3.273 | 1.421 | 0.43 | 1.0 | 2.0 | 4.00 | 4.0 | 6.0 | <.0001 |
| PlaquesdT0T2 | 11 | 3.909 | 1.221 | 0.37 | 2.0 | 3.0 | 4.00 | 4.0 | 6.0 | <.0001 |
| HyppigmdT0T2 | 11 | -1.636 | 1.433 | 0.43 | -4.0 | -2.0 | -2.00 | 0.0 | 0.0 | 0.0036 |
| SizedT0T2 | 11 | 0.000 | 0.000 | 0.00 | 0.0 | 0.0 | 0.00 | 0.0 | 0.0 | |
| TotaldT0T2 | 11 | 9.364 | 2.580 | 0.78 | 6.0 | 7.0 | 9.00 | 12.0 | 14.0 | <.0001 |

Table 3. Comparison of the relative differences (%) between Target and Control (PT0T2 et PC0C2).

| Variable | N | Mean | SD | SE | Min | Q1 | Median | Q3 | Max | Student p-value |
|---------------|----|--------|--------|------|------|-------|--------|-------|-------|-----------------|
| dErythpT0T2C | 11 | 73.636 | 18.148 | 5.47 | 50.0 | 50.0 | 75.00 | 83.3 | 100.0 | <.0001 |
| dScalingpT0T | 11 | 93.939 | 10.601 | 3.20 | 75.0 | 83.3 | 100.00 | 100.0 | 100.0 | <.0001 |
| dPlaquespT0T2 | 11 | 97.727 | 7.538 | 2.27 | 75.0 | 100.0 | 100.00 | 100.0 | 100.0 | <.0001 |
| dHyppigmpT0T | 0 | . | . | . | . | . | . | . | . | |
| dSizetT0T2C0 | 11 | 3.030 | 10.050 | 3.03 | 0.0 | 0.0 | 0.00 | 0.0 | 33.3 | 0.34 |
| dTotalpT0T2C | 11 | 58.235 | 12.910 | 3.89 | 37.5 | 46.2 | 60.00 | 68.3 | 75.0 | <.0001 |

3.3. Recurrence

After a follow-up of 6 months after treatment, 2 out of 11 target lesions (18%) presented de novo erythema, slight infiltration and scaling, suggestive of MF recurrence. The hyperpigmentation observed at the evaluation at 2 months was significantly attenuated in 10 out of 11 cases at 6 months.

No beneficial or detrimental effects were noted for the surrounding control lesions.

3.4. Adverse Effects

Five days after the first and second application of IM, all the patients experienced treatment-related adverse effects. The scores for burning sensations, oozing and crusting were 1.6, 0.7, 1, and 1.2, 0.3, 0.5, respectively. All the patients accepted well the IM-inherent adverse effects and were never a reason to interrupt the trial.

4. DISCUSSION

Although the precise action mechanisms of IM on neoplastic lymphocytes should be further investigated, the IM-induced pro-inflammatory and pro-apoptotic storm [12] through activation of the PKC isoform PKC δ is likely to be involved in the anti-neoplastic action on MF lymphocytes [14].

As the control lesions in the direct vicinity of the target lesions were unaltered one may suggest that IM only acts locally at the site of application and does not generate a more expanded immune effect. This is in contrast to topical agents such as resiquimod, inducing not only a loco-regional immune effect, but also a systemic immune stimulation by enhancing circulating dendritic cells [20]. On the other hand, other authors described an adjuvant effect of IM by showing that its action on subcutaneous tumors simultaneously generated anti-cancer CD8⁺ T-cells, able to regress metastases and distant metastases by upregulating CD80 and CD86 expression on dendritic cells and by stimulating CD8⁺ T-cell induction when co-delivered with a protein antigen [21].

This pilot study supports the hypothesis that the action spectrum of IM is not only limited to neoplastic keratinocytes and melanocytes, but also expands to neoplastic lymphocytes of MF.

Due to the relative difficulty of finding 3 highly similar test MF lesions (IM target lesion gel, placebo gel lesion and no treatment lesion) in one patient, we decided in this pilot setting not to include a placebo gel group. Previous studies with IM on AK demonstrated that IM was significantly superior to placebo gel in terms of partial and complete clearance and the median percentage reduction in baseline AK lesions for patients treated with IM gel ranged from 75% to 100% compared with 0% for vehicle gel ($P < .0001$ vs vehicle) [2]. Furthermore, the 13.3% placebo effect in the AK studies could also be attributed to the natural evolution of “coming and going” of AK’s. In addition, the vehicle gel could have had a keratolytic effect on the hyperkeratotic part of the AK’s, explaining a placebo effect, a phenomenon that does not exist in MF lesions.

Even if only 11 target lesions of 10 T2b MF patients were included in this pilot study, the results remain interesting, in particular in comparison to other available topical treatments. In fact, for T2 MF, the topical retinoids group, including bexarotene 1% gel, tazarotene 0,1% gel and alitretinoine 0,1% gel, presented a complete cure of 21%, 33% and 100% (one single patient), respectively [22 - 24]. The potent to very strong corticosteroids achieved a complete response in 25% in T2 MF patients [25, 26]. The topical immunomodulators such as imiquimod 5% cream presented a 50% cure rate [27] and resiquimod 0.03% and 0.06% gel presented a 30% cure rate in 12 IA-IIA MF patients [20]. Topical chemotherapies using mechlorethamine or carmustine in T2 MF patients achieved about a 50% complete response [28 - 31].

IM already achieved a good clinical response after 2 months versus 10-19 months with mechlorethamine or carmustine [28 - 32] or versus 20.1 months for bexaroten gel [22]. Hence, IM gel seems to act more rapidly compared to other topical agents.

That TCR mono-clonality was still present in 3 of 7 target lesions at T2 is probably related to the high sensitivity of the PCR technique, whereas the histological and immunohistological analysis do not favor anymore a diagnosis of MF. Despite this fact, there was only an 18% recurrence rate after 6 months. This may suggest that the histological and immunohistological assessment of treatment results are better predictors of a persisting favorable treatment response than TCR rearrangement analysis.

The number of cases is too small to determine whether the intensity of adverse reactions and/or the post-inflammatory hyperpigmentation after application are predictive of a favorable treatment outcome or not.

The adverse effects of IM were identical to those experienced using IM gel as AK therapy [1, 2]. In general, the adverse effects were less severe following the second IM application, probably linked to an already partial remission of the target lesion after the first IM application. Hyperpigmentation of the target lesion was frequent (8 out of 11 target lesions) but faded over time.

Final dosing regimens and the place of IM among the armamentarium of topical treatments against MF should be evaluated on larger series. Whether other ingenol derivatives are also effective as anti-MF topical agent remains to be determined [33]. One major drawback of IM is that it is only approved for a body surface limited to 25 cm². Currently ingenol disoxate is being developed for use on larger surfaces, up to 250 cm², as has been recently published for field AK [34].

CONCLUSION

In conclusion, this pilot study suggests that IM gel merits further evaluation as a topical alternative treatment for patients with localized patch/plaque stage MF skin lesions not exceeding 25 cm², in a placebo-controlled study design. This study provides an initial proof of concept that IM also acts against neoplastic MF lymphocytes.

FINANCIAL-DISCLOSURE

Leo Pharma provided the IM gel but the authors perceived no financial compensation in what so ever form. Leo Pharma did not intervene in the design and interpretation of the study results.

ETHICAL APPROVAL AND CONSENT TO PARTICIPATE

This prospective pilot study was performed in accordance with the ethical standards of the University Hospital Committee on institutional human experimentation.

HUMAN AND ANIMAL RIGHTS

No Animals were used in this research. All human research procedures followed were in accordance with the ethical standards of the committee responsible for human experimentation (institutional and national), and with the Helsinki Declaration of 1975, as revised in 2008.

CONSENT FOR PUBLICATION

The aims of the study and all the procedures were explained to all the patients and all signed an informed consent (EudraCT number: 2017-000612-42).

CONFLICT OF INTEREST

The authors declare no conflict of interest, financial or otherwise.

ACKNOWLEDGEMENTS

Declared none.

REFERENCES

- [1] Lebwohl M, Shumack S, Stein Gold L, Melgaard A, Larsson T, Tyring SK. Long-term follow-up study of ingenol mebutate gel for the treatment of actinic keratoses. *JAMA Dermatol* 2013; 149: 666-70. [<http://dx.doi.org/10.1001/jamadermatol.2013.2766>] [PMID: 23553119]
- [2] Keating GM. Ingenol mebutate gel 0.015% and 0.05%: in actinic keratosis. *Drugs* 2012; 72: 2397-405. [<http://dx.doi.org/10.2165/11470090-000000000-00000>] [PMID: 23231025]
- [3] Sligh JE Jr. New therapeutic options for actinic keratosis and basal cell carcinoma. *Semin Cutan Med Surg* 2014; 33(4)(Suppl 76): S76-80. [<http://dx.doi.org/10.12788/j.sder.0100>] [PMID: 25268601]
- [4] Cantisani C, Paolino G, Cantoresi F, Faina V, Richetta AG, Calvieri S. Superficial basal cell carcinoma successfully treated with ingenol mebutate gel 0.05%. *Dermatol Ther (Heidelb)* 2014; 27: 352-4. [<http://dx.doi.org/10.1111/dth.12148>] [PMID: 25052730]
- [5] Siller G, Rosen R, Freeman M, Welburn P, Katsamas J, Ogbourne SM. PEP005 (ingenol mebutate) gel for the topical treatment of superficial basal cell carcinoma: results of a randomized phase IIa trial. *Australas J Dermatol* 2010; 51: 99-105. [<http://dx.doi.org/10.1111/j.1440-0960.2010.00626.x>] [PMID: 20546215]
- [6] Micali G, Lacarrubba F, Nasca MR, Ferraro S, Schwartz RA. Topical pharmacotherapy for skin cancer: part II. Clinical applications. *J Am Acad Dermatol* 2014; 70: e1-e12. [<http://dx.doi.org/10.1016/j.jaad.2013.12.037>] [PMID: 24831325]
- [7] Braun SA, Homey B, Gerber PA. Successful treatment of Bowen disease with ingenol mebutate. *Hautarzt* 2014; 65(10): 848-50. [<http://dx.doi.org/10.1007/s00105-014-3509-5>] [PMID: 25217087]
- [8] Cozzi SJ, Le TT, Ogbourne SM, James C, Suhrbier A. Effective treatment of squamous cell carcinomas with ingenol mebutate gel in immunologically intact SKH1 mice. *Arch Dermatol Res* 2013; 305: 79-83. [<http://dx.doi.org/10.1007/s00403-012-1270-0>] [PMID: 22871992]
- [9] Ogbourne SM, Suhrbier A, Jones B, *et al.* Antitumor activity of 3-ingenyl angelate: Plasma membrane and mitochondrial disruption and necrotic cell death. *Cancer Res* 2004; 64: 2833-9. [<http://dx.doi.org/10.1158/0008-5472.CAN-03-2837>] [PMID: 15087400]

- [10] Ersvaer E, Kittang AO, Hampson P, *et al.* The protein kinase C agonist PEP005 (ingenol 3-angelate) in the treatment of human cancer: A balance between efficacy and toxicity. *Toxins (Basel)* 2010; 2: 174-94. [<http://dx.doi.org/10.3390/toxins2010174>] [PMID: 22069553]
- [11] Mansuy M, Nikkels-Tassoudji N, Arrese JE, Rorive A, Nikkels AF. Recurrent in situ melanoma successfully treated with ingenol mebutate. *Dermatol Ther (Heidelb)* 2014; 4: 131-5. [<http://dx.doi.org/10.1007/s13555-014-0051-4>] [PMID: 24691652]
- [12] Edwards SK, Moore CR, Liu Y, Grewal S, Covey LR, Xie P. N-benzyladriamycin-14-valerate (AD 198) exhibits potent anti-tumor activity on TRAF3-deficient mouse B lymphoma and human multiple myeloma. *BMC Cancer* 2013; 13: 481. [<http://dx.doi.org/10.1186/1471-2407-13-481>] [PMID: 24131623]
- [13] Alchin DR. Ingenol mebutate: A succinct review of a succinct therapy. *Dermatol Ther (Heidelb)* 2014; 4: 157-64. [<http://dx.doi.org/10.1007/s13555-014-0061-2>] [PMID: 25159813]
- [14] Lee WY, Hampson P, Coulthard L, *et al.* Novel antileukemic compound ingenol 3-angelate inhibits T cell apoptosis by activating protein kinase C θ . *J Biol Chem* 2010; 285: 23889-98. [<http://dx.doi.org/10.1074/jbc.M109.041962>] [PMID: 20472553]
- [15] Jawed SI, Myskowski PL, Horwitz S, Moskowitz A, Querfeld C. Primary cutaneous T-cell lymphoma (mycosis fungoides and Sézary syndrome): Part I. Diagnosis: clinical and histopathologic features and new molecular and biologic markers. *J Am Acad Dermatol* 2014; 70(205): e1-e16. [<http://dx.doi.org/10.1016/j.jaad.2013.07.049>] [PMID: 24438969]
- [16] Jawed SI, Myskowski PL, Horwitz S, Moskowitz A, Querfeld C. Primary cutaneous T-cell lymphoma (mycosis fungoides and Sézary syndrome): Part II. Prognosis, management, and future directions. *J Am Acad Dermatol* 2014; 70(223): e1-e17. [<http://dx.doi.org/10.1016/j.jaad.2013.08.033>] [PMID: 24438970]
- [17] Demirkesen C, Esirgen G, Engin B, Songur A, Oğuz O. The clinical features and histopathologic patterns of folliculotropic mycosis fungoides in a series of 38 cases. *J Cutan Pathol* 2015; 42: 22-31. [<http://dx.doi.org/10.1111/cup.12423>] [PMID: 25376535]
- [18] Marschalkó M, Erős N, Kontár O, *et al.* Folliculotropic mycosis fungoides: clinicopathological analysis of 17 patients. *J Eur Acad Dermatol Venereol* 2015; 29: 964-72. [<http://dx.doi.org/10.1111/jdv.12743>] [PMID: 25406034]
- [19] Olsen EA, Whittaker S, Kim YH, *et al.* Clinical end points and response criteria in mycosis fungoides and Sézary syndrome: A consensus statement of the International Society for Cutaneous Lymphomas, the United States Cutaneous Lymphoma Consortium, and the Cutaneous Lymphoma Task Force of the European Organisation for Research and Treatment of Cancer. *J Clin Oncol* 2011; 29: 2598-607. [<http://dx.doi.org/10.1200/JCO.2010.32.0630>] [PMID: 21576639]
- [20] Rook AH, Gelfand JC, Wsocka M, *et al.* Topical resiquimod can induce disease regression, eradicate malignant T cells and enhance T cell effector functions in cutaneous T cell lymphoma 2015. *blood-2015-02-630335*.
- [21] Le TT, Gardner J, Hoang-Le D, *et al.* Immunostimulatory cancer chemotherapy using local ingenol-3-angelate and synergy with immunotherapies. *Vaccine* 2009; 27: 3053-62. [<http://dx.doi.org/10.1016/j.vaccine.2009.03.025>] [PMID: 19428919]
- [22] Breneman D, Duvic M, Kuzel T, Yocum R, Truglia J, Stevens VJ. Phase 1 and 2 trial of bexarotene gel for skin-directed treatment of patients with cutaneous T-cell lymphoma. *Arch Dermatol* 2002; 138: 325-32. [<http://dx.doi.org/10.1001/archderm.138.3.325>] [PMID: 11902983]
- [23] Apisarnthanarax N, Talpur R, Ward S, Ni X, Kim HW, Duvic M. Tazarotene 0.1% gel for refractory mycosis fungoides lesions: An open-label pilot study. *J Am Acad Dermatol* 2004; 50: 600-7. [<http://dx.doi.org/10.1016/j.jaad.2003.09.005>] [PMID: 15034511]
- [24] Bassiri-Tehrani S, Ba BA, Cohen DE. Treatment of cutaneous T-cell lymphoma with alitretinoin gel. *Int J Dermatol* 2002; 41: 104-6. [<http://dx.doi.org/10.1046/j.1365-4362.2002.01363.x>] [PMID: 11982647]
- [25] Zackheim HS, Kashani-Sabet M, Amin S. Topical corticosteroids for mycosis fungoides. Experience in 79 patients. *Arch Dermatol* 1998; 134: 949-54. [<http://dx.doi.org/10.1001/archderm.134.8.949>] [PMID: 9722724]
- [26] Zackheim HS. Treatment of patch-stage mycosis fungoides with topical corticosteroids. *Dermatol Ther (Heidelb)* 2003; 16: 283-7. [<http://dx.doi.org/10.1111/j.1396-0296.2003.01639.x>] [PMID: 14686970]
- [27] Deeths MJ, Chapman JT, Dellavalle RP, Zeng C, Aeling JL. Treatment of patch and plaque stage mycosis fungoides with imiquimod 5% cream. *J Am Acad Dermatol* 2005; 52: 275-80. [<http://dx.doi.org/10.1016/j.jaad.2004.04.049>] [PMID: 15692473]
- [28] Kim YH. Management with topical nitrogen mustard in mycosis fungoides. *Dermatol Ther (Heidelb)* 2003; 16: 288-98. [<http://dx.doi.org/10.1111/j.1396-0296.2003.01640.x>] [PMID: 14686971]
- [29] Kim YH, Martinez G, Varghese A, Hoppe RT. Topical nitrogen mustard in the management of mycosis fungoides: Update of the Stanford experience. *Arch Dermatol* 2003; 139: 165-73. [<http://dx.doi.org/10.1001/archderm.139.2.165>] [PMID: 12588222]

- [30] Talpur R, Venkatarajan S, Duvic M. Mechlorethamine gel for the topical treatment of stage IA and IB mycosis fungoides-type cutaneous T-cell lymphoma. *Expert Rev Clin Pharmacol* 2014; 7: 591-7. [<http://dx.doi.org/10.1586/17512433.2014.944500>] [PMID: 25068889]
- [31] Apisarnthanarax N, Wood GS, Stevens SR, *et al.* Phase I clinical trial of O6-benzylguanine and topical carmustine in the treatment of cutaneous T-cell lymphoma, mycosis fungoides type. *Arch Dermatol* 2012; 148: 613-20. [<http://dx.doi.org/10.1001/archdermatol.2011.2797>] [PMID: 22250189]
- [32] Zackheim HS, Epstein EH Jr, Crain WR. Topical carmustine (BCNU) for cutaneous T cell lymphoma: A 15-year experience in 143 patients. *J Am Acad Dermatol* 1990; 22: 802-10. [[http://dx.doi.org/10.1016/0190-9622\(90\)70112-U](http://dx.doi.org/10.1016/0190-9622(90)70112-U)] [PMID: 2347966]
- [33] Liang X, Grue-Sørensen G, Månsson K, *et al.* Syntheses, biological evaluation and SAR of ingenol mebutate analogues for treatment of actinic keratosis and non-melanoma skin cancer. *Bioorg Med Chem Lett* 2013; 23: 5624-9. [<http://dx.doi.org/10.1016/j.bmcl.2013.08.038>] [PMID: 23993332]
- [34] Bourcier M, Stein Gold L, Guenther L, Andreassen CM, Selmer J, Goldenberg G. A dose-finding trial with a novel ingenol derivative (ingenol disoxate: LEO 43204) for field treatment of actinic keratosis on full face or 250 cm² on the chest. *J Dermatolog Treat* 2017; 28: 652-8. [<http://dx.doi.org/10.1080/09546634.2017.1303568>] [PMID: 28264612]

© 2017 Lebas *et al.*

This is an open access article distributed under the terms of the Creative Commons Attribution 4.0 International Public License (CC-BY 4.0), a copy of which is available at: (<https://creativecommons.org/licenses/by/4.0/legalcode>). This license permits unrestricted use, distribution, and reproduction in any medium, provided the original author and source are credited.